

Hurler syndrome: a case report

S. Thomas* / S. Tandon**

Hurler syndrome is an inherited disorder of mucopolysaccharide metabolism, which is caused by a defect in genetically controlled pathways of lysosomal degradation. It represents the classical prototype of mucopolysaccharide disorder. An interesting case of a three and a half-year old boy with a rare combination of skeletal, neurological, ophthalmologic, and dental findings is presented. It is a rare syndrome with a very low prevalence of 1:100000 births and as such the clinician should be aware of this syndrome.

J Clin Pediatr Dent 24(4): 335-338, 2000

INTRODUCTION

Mucopolysaccharidoses represents a broad spectrum of disorders due to the deficiency of one of a group of enzymes, which degrade three classes of mucopolysaccharides: heparan sulfate, dermatan sulfate and keratan sulfate.¹

Hurler syndrome represents the classic prototype of mucopolysaccharide disorder. It manifests itself in early infancy, consisting of mental retardation, an enlarged deformed head, coarse and expressionless facial features, corneal clouding, skeletal abnormalities, flexion contractures, hernias and hepatosplenomegaly.² It is an inherited disorder of mucopolysaccharide metabolism, which is caused by a defect in genetically controlled pathways of lysosomal degradation. Its frequency is quite low and is approximately 1:100000 births.³

It is an autosomal recessive disease caused by mutations in alpha L iduronidase gene. These mutations lead to a deficiency of the glycosidase alpha L iduronidase enzyme, which is required for the degradation of heparan sulfate and dermatan sulfate.¹ The storage of these glycosaminoglycans, either in partially degraded or undegraded forms, interferes with the normal function of the affected cells and leads to the characteristic

clinical symptoms. Being an autosomal recessive disease, only 1 out of 4 offsprings will be affected even if both the parents are carriers of the abnormal gene.

The most frequent mutation associated is nonsense mutation, where there is either substitution of the amino acid tryptophan with a stop codon in position 402, or substitution of glutamine in position 70. Missense, nonsense, insertional deletions and duplications of coding regions are also seen.

The following is a case report of a classic prototype of a mucopolysaccharide disorder.

CASE REPORT

Pradeep, a three and a half-year old boy was referred from the Department of Pediatrics on February 21, 1998 for a dental evaluation. His complaint on reporting was a swelling in the back (Figure 1).

Medical history revealed that he was born to nonconsanguineous parents and had no antenatal or postnatal complications. He was an average size full term baby with a defect noticed in his right eye. When he started to walk, a small lump was noticed in his back, which gradually increased in size. He had slightly retarded growth with a short stature for his chronological age. Other than multiple bony deformities, he also presented with an exaggerated kyphosis, rotated legs and short and stubby hands.

Examination of the head showed open fontanelles and a dolichocephalic head. He also exhibited frontal and parietal bulges, hypertelorism, oblique palpebral fissures and right corneal opacity. His nasal bridge was depressed with a broad nasal tip. The mouth was large and his lips were enlarged and patulous (Figure 2).

Intraoral clinical examination revealed a large tongue with widely spaced teeth set in thick gingival tissue. An anterior open bite was also seen. His dental age was delayed as was evidenced by the fact that all his maxillary teeth and his mandibular second primary molars were, as yet, unerupted (Figure 3).

* S. Thomas, BDS, Postgraduate student, Department of Pedodontics and Preventive Dentistry, College of Dental Surgery, Manipal 5761 19, India.

** S. Tandon, MDS, Associate Dean and Head of the Department, Department of Pedodontics and Preventive Dentistry, College of Dental Surgery, Manipal 5761 19, India.

Address all correspondence to Dr. Shobha Tandon, Associate Dean, Professor and Head, Department of Pedodontics and Preventive Dentistry, College of Dental Surgery, Manipal 5761 19, India.
Phone number: 0091-08252-71201 Ext 2182

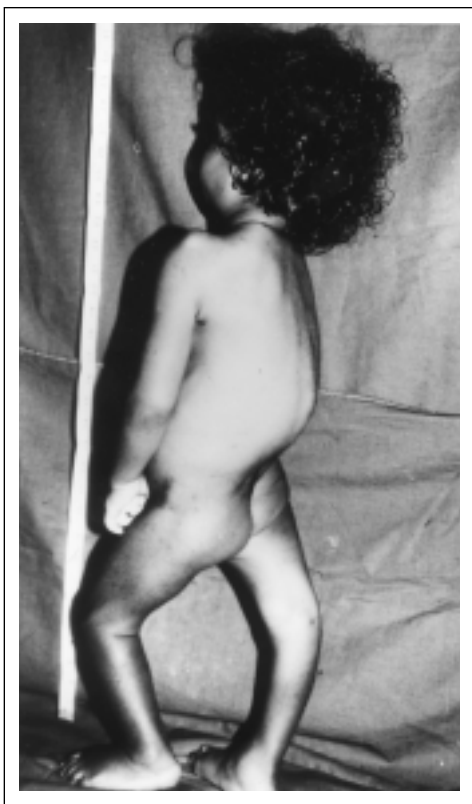

Figure 1.

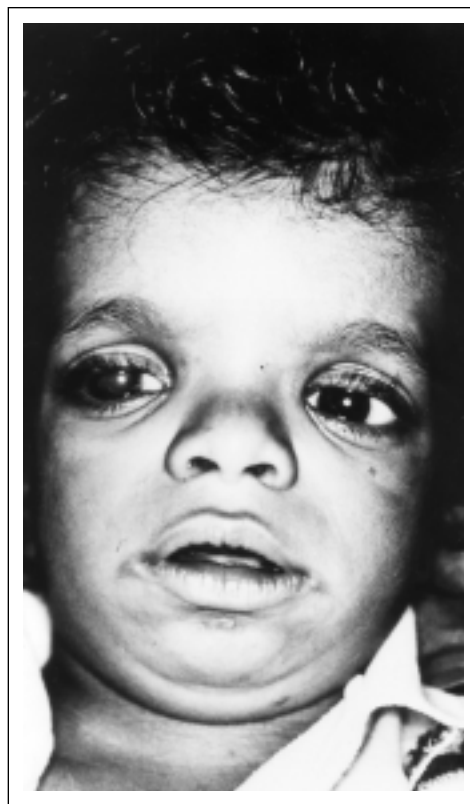


Figure 2.

In order to find the cause of his delayed dental age, a frontal cephalogram was obtained. It showed multiple localized areas of radiolucencies associated with unerupted teeth on the anterior and left lateral aspect of the mandible resembling dentigerous cysts (Figure 4).

A hand-wrist radiograph was also taken to confirm his delayed dental age. It showed tapering of the terminal phalanges with widening at the distal ends and tapering at the proximal ends giving the characteristic "bullet appearance" (Figure 5).

A differential diagnosis of multiple sulfatase deficiency, generalized gangliosidosis, mannosidosis, fucosidosis, mucopolipidosis was arrived at due to similarity in clinical features. A provisional diagnosis of Hurler syndrome was entertained due to the following reasons: growth failure, craniofacial dysmorphism, multiple bony deformities of the bone and corneal clouding.

Definitive diagnoses in such cases depends on biochemical tests such as enzyme analysis in the urine. Although mucopolysaccharide excretion was within the normal reference range, in the present case, creatinine value was low, which can be related to his retarded growth and poor nourishment.

The child was then undertaken for a comprehensive oral health care program. The importance of prevention was explained to the parents and meticulous oral hygiene instructions and diet counseling was given to the child.

DISCUSSION

This rather rare syndrome is an autosomal recessive disease caused by mutations in alpha-L-iduronidase gene. This gene is required for the degradation of mucopolysaccharides. A defect in the gene results in accumulation of undegraded or partially degraded mucopolysaccharide, which then interferes with the function of the affected cells and causes large lips, thick gingival tissue and corneal opacities. Intracellular accumulation of glucosaminoglycans leads to disruption of the intracellular and extracellular environment and dysfunction of multiple organ systems leading to profound disruption of the normal mechanisms of growth and development.⁵

Progressive accumulation of mucopolysaccharides in the soft tissues causes complications like cardiac failure and bronchopneumonia resulting unfortunately in the death of these patients by 10 years of age.⁶ Oral changes have been reviewed by Gardner.⁷ The lips are enlarged and patulous. The mouth is usually held open with protruding tongue from about 3 years of age. Eruption is delayed in at least half the patients. The alveolar ridges are nearly always hyperplastic resulting in the spacing of teeth. The mandible is short and broad.

Extremely common are localized areas of bone destruction which resemble dentigerous cysts. These are often present by 3 years of age and involve the second primary molar and first and second permanent

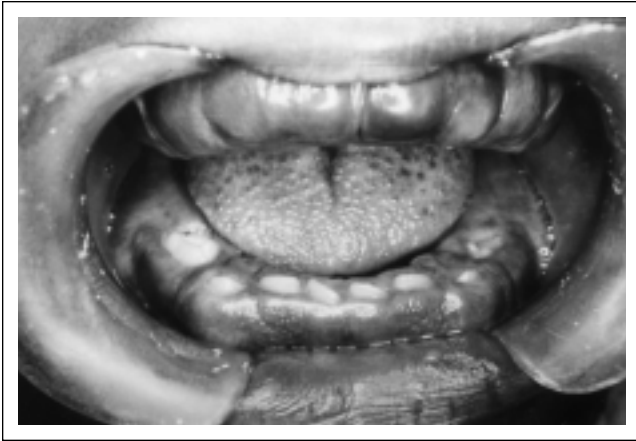

Figure 3.

mandibular permanent molars. The margins of the radiolucencies are usually smooth and clearly defined.⁶ Radiolucencies in the radiograph are caused by accumulation of mucopolysaccharides in the tissues.⁸

It has been seen that infusing the missing enzyme results in significant clinical and biochemical improvement. Allogeneic bone marrow transplantation is also effective. Early bone marrow transplantation of a child with Hurler syndrome, who has normal intelligence is likely to have a high benefit. However, due to a lack of matched related donors and unacceptable morbidity of matched unrelated transplants, this therapy is not available to all the patients.

Introducing genetically connected host cells in transplanted normal cells into the affected patient is another alternative.¹⁰ syndrome can definitely be prevented by antenatal diagnosis as most of these tests are feasible and readily available. Where the condition has an ethnic predilection, sound genetic advice may be given to help eradicate the disease.

The dentist has a very limited role to play in such cases. Prevention of dental disease is usually the aim of the treatment. Management of dental problems is essentially no different from that of any other patient. Factors taken into account are:

1. The degree of mental retardation
2. The presence or absence of seizure disorder
3. The degree of joint stiffening and the extent of other related medical problems.

Depending on which of these factors are present and the extent of involvement, dental care may warrant sedation, hospitalization or general anesthesia for optimum results.¹⁰

CONCLUSION

Although Hurler syndrome is not encountered routinely in the dental clinic, this case illustrates the impor-

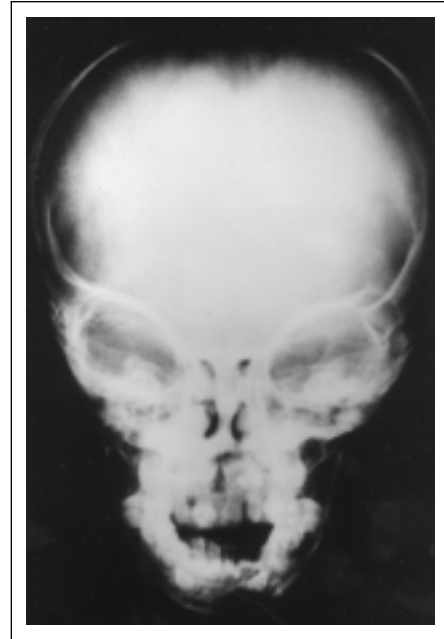

Figure 4.

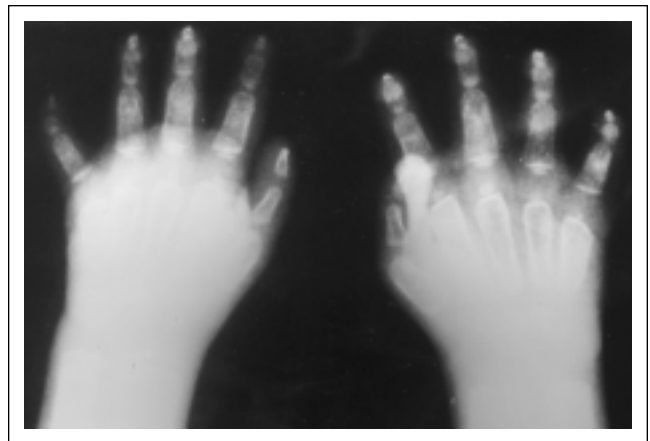


Figure 5.

tance of dentists being acquainted with such rare conditions. Such cases if properly followed up definitely restore not only dental health, but also assist in maintaining the general health of these patients as long as they survive.

REFERENCES

1. Scott HS, Litiens T, Hopwood JJ, Morris CP. A common mutation for mucopolysaccharidosis type I associated with a severe Hurler syndrome phenotype. *Hum Mut* 1: 103-108, 1992.
2. Jones JH, Mason DK. Oral manifestations of systemic disease. WB Saunders, London, 1st edition, 37, 1980.
3. Lowry RB, Renwick DHG. Relative frequency of the Hurler and Hunter syndrome. *N Engl J Med* 284: 221-222, 1971. Cited in Gorlin RJ, Pindborg JJ, Cohen MM. *Syndromes of the head and neck*. McGraw Hill Company, USA, 2nd edition, 476, 1976.
4. Nelson WE. *Textbook of Pediatrics*. WB Saunders Company, Philadelphia, 15th edition, 398-399, 1996.

5. Silveri CP, Kaplan FS, Fallon MD, Bayever E, August CS. Hurler syndrome with special reference to histologic abnormalities of the growth plate. *Clin Orthop* 69: 305-311, 1991.
6. Gorlin RJ, Pindborg JJ, Cohen MM. *Syndromes of the head and neck*. McGraw Hill Company, USA, 2nd edition, 476, 1976.
7. Gardner D.G. Metachromatic cells in the gingiva in Hurler's syndrome. *Oral Surgery* 26: 782-789, 1968. Cited in Gorlin RJ, Pindborg JJ, Cohen MM. *Syndromes of the head and neck*. McGraw Hill Company, USA, 2nd edition, 476, 1976.
8. Bhaskar SN. *Synopsis of oral pathology*, CV Mosby, St. Louis, 5th edition, 625, 1977.
9. Whitley CB, Belani KG, Chang PN, Summers CG, Blazar BR, Tsai MY, et al. Long term outcome of Hurler syndrome following bone marrow transplantation. *Am J Med Genetics* 46: 209-218, 1993.
10. Neville BW, Damm DD, Allen CM, Bouquot JE. *Oral and maxillofacial pathology*. WB Saunders Co, Philadelphia, 1st edition, 595, 1995.