

Fusion of the permanent maxillary right incisor to a supernumerary tooth in association with a gemination of permanent maxillary left central incisor: a dental, genetic and dermatoglyphic study

Metin Atasu* / Hale Cimilli**

The relationship between fusion of the permanent maxillary right central incisor to a supernumerary tooth in association with gemination of permanent maxillary left central incisor and dermatoglyphics were investigated.

J Clin Pediatr Dent 24(4): 321-333, 2000

INTRODUCTION

Teeth maybe maldeveloped in both shape and structure. There are double or twin teeth. These teeth may take place of a regular tooth or of neighboring teeth, or they may occur in addition to regular teeth. It may concluded, for that reason, that they develop from incomplete division of a single tooth bud called schizodontism, or from complete division of a single dental germ called gemination or from union of two neighboring, regular or accessory dental germs called synodontism or fusion. It follows that no decision on the mode of development is possible from extracted tooth alone. There is a wide variation in the degree of fusion between individual parts of these double or multiple teeth.

All kinds of transitional forms exist from that of a nearly single germ unusually large tooth to an almost complete separation into two or more individual teeth in which union is kept up maintained only cementum. One is called fusion or concrescence means two neighboring teeth joined together by cementum only. This bond may form during development of the two teeth or after development is completed i.e. by hypercementosis.

Fusion is an organic union of two or more individual teeth by the criterion being union of the dentin, the condition of pulp chamber and enamel being immater-

ial.¹⁻⁶ In brief, among double teeth gemination⁷⁻¹⁶ is a developmental dental anomaly characterized by the formation of the equivalent of two teeth from the same dental germ and fusion¹⁷⁻⁴⁹ is also a developmental tooth anomaly characterized by the union of two neighboring teeth, and Atkins *et al.* have reported a gemination in primary maxillary right central incisor, and fusion of the permanent maxillary left central incisor to a supernumerary tooth. Jarvinen *et al.*²⁸ noted that the combined prevalence of fusion and gemination was 0.7%.

The integumentary system consists of the skin, sweat glands, nails, hair, sebaceous glands and erector pill muscles and includes the mammary glands and teeth. The skin is a complex organ system that forms a sheet on the surface of the embryo. The skin is made of two morphologically different germ layers: ectoderm and mesoderm. The superficial layer or epidermis is a specialized epithelial tissue that is derived from the surface ectoderm. The deep thicker layer, or dermis, is composed of dense, irregularly arranged connective tissue that is derived from the mesoderm underlying the ectoderm. Proliferation of cells in the stratum germinativum also forms down growth called epidermal ridges, which extend into the developing dermis. These ridges are permanently established by seventeenth week. The epidermal ridges produce ridges and grooves on the surface of the palms and soles, including the digits. The type of pattern that develops is determined genetically and constitutes the basis for using points in criminal investigations and medical genetics. The study of ridged skin is called dermatoglyphics.^{50,51} Abnormal chromosomal complements affect the development of the ridge patterns. Environmental agents such as diet, drugs, x-rays and viruses cause unusual arrangements of the ridged skin of the fetus.⁵²

The teeth develop from ectoderm and mesoderm. The enamel organ is derived from ectoderm of the oral

* Metin Atasu was a Professor of Medical Genetics Marmara University, Faculty of Dentistry, Istanbul, Turkey, Hale Cimilli is Assistant Doctor of Endodontics, Marmara University, Faculty of Dentistry, Istanbul, Turkey.

All correspondence should be sent to Hale Cimilli.

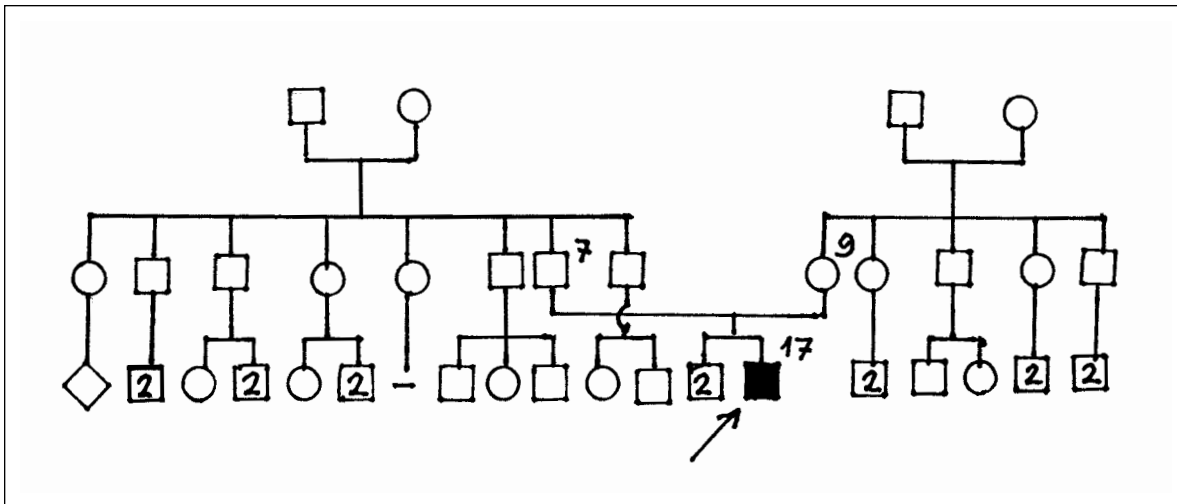


Figure 1. Fusion associated with gemination.

cavity, all other tissues differentiate from the surrounding mesenchyme, a derivative of mesoderm. Tooth development appears to be initiated by the inductive influence of the mesenchyme on the overlying ectoderm. This mesenchyme is of neural crest origin. Tooth development is a continuous process, but it is usually divided into stages for descriptive purposes such as bud, cap and bell on the basis of the appearance of the developing tooth. The first tooth buds appear in the anterior mandibular region; later, tooth development occurs in the anterior maxillary region, and then progresses posteriorly in both jaws. Tooth development begins during the sixth week of the prenatal life and continues for years after birth.^{50,51}

In summary, both epidermal ridges and teeth develop from both ectoderm and mesoderm and an injury, which occurs during embryogenesis affects the normal growth. For that reason, we investigated the relationship between fusion of the permanent maxillary right central incisor to a supernumerary tooth in association with gemination of permanent maxillary left central incisor and dermatoglyphics and presented an additional case of the combined condition.

CASE REPORT

A 17-year-old male (Figure 1) (111-17) with enlarged tooth masses in the anterior of maxilla referred to the Department of Endodontics by chief complaints their sensitivity. He was third child of the family. There were no hereditary peculiarities of the parents and was no consanguineous marriages between the parents. The history revealed that the mother did not receive medicine during her pregnancy and did not expose to radiation and trauma.

During intra-oral examination unusually large and wide crowns of both maxillary permanent central incisors were observed (Figures 2 and 3). There were

vertical furrows on the buccal surfaces of the incisor teeth. The left maxillary central incisor had a fissure on the incisal edge. The incisors were placed in front of the lateral incisors and canines. The periapical roentgenographs of the central incisors showed us that the right permanent maxillary central incisor had two separate pulp chambers united only by dentin with fused two roots, and the left permanent maxillary left central incisor had only one large pulp and was single rooted (Figure 4). Thus, the right central incisor was considered as a fused tooth and the neighboring left was accepted as geminated occurred by a division of a single tooth germ by invagination. The fissure observed on geminated tooth supported the evidence of invagination. Both of the central incisors respond to vitality tests with ethyl chloride and electric pulp tester and tender to percussion.

The sensitive and caries-free incisors were anesthetized and isolated with a rubber dam. The access cavities were prepared in both geminated and fused incisor. Pulp tissues were removed with barbed broaches and the root canals were instrumented by K-files (Zippeser Munchen, Germany). The coronal portions of the root canals were flared with a series of Gates Glidden (Malelle, Ballagues, Switzerland) 1-12 to H6 burns. Biomechanic preparations were completed with step-back technique and copious amounts of 5.25% sodium hypochloride solution for irrigation. Calcium hydroxide powder (Merck, Darmstad, Germany) was mixed with lidocaine solution and introduced into both root canal systems. The patient came two weeks later. At the second visit the teeth were asymptomatic and root canals were obturated with Ultrafil technique (Hygenic, Acron, OH). The crowns were restored with an anterior composite resin (Brillant, Coltene Inc. Carlsbad CA).

The dermatoglyphic findings of the patient are shown in Table I and Figure 5. There were ulnar loops on all fin-

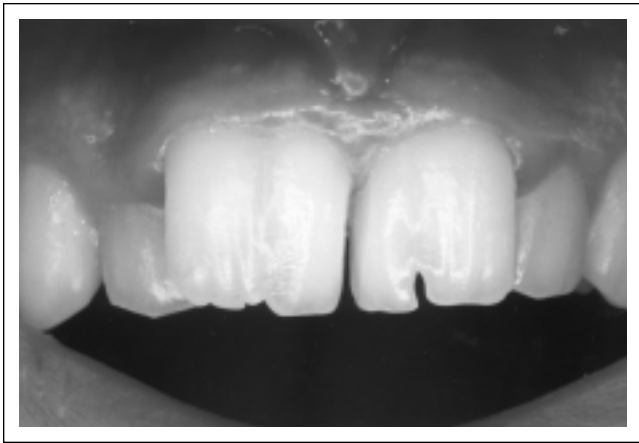


Figure 2. Buccal appearances of maxillary germinated and fused central incisors.

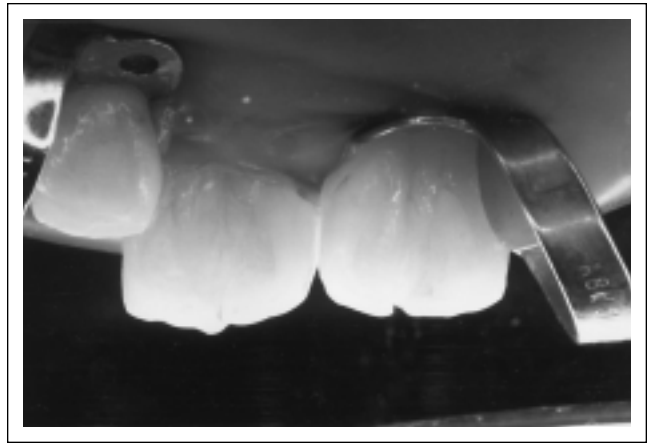

Figure 3. Lingual appearances of maxillary germinated and fused central incisors.

gers except IInd digits. The individual ridge-count on IVth right finger was high (27 ridges). The total finger ridge-count (TRC) was somewhat lower than those of the male control cases. The mean for TRC's of the male control cases was $x = 151.71 \pm 2.12$ ($n = 446$). There was an A-line terminating on the radial border of the left palm. There was a hypothenar radial arch associated with t^b triradius on the right palm. The pattern intensity was high on the left sole.

DISCUSSION

The pathogenesis of the tooth invagination resulting in gemination is not clear yet. The condition is produced by invagination of a portion of the crown into the pulp cavity. This comes about by active proliferation of a limited area of epithelium followed by its peg-like growth into the dental papilla. On the other hand the epithelium is passively retarded at particular bordered sites which later become the bottom of the cavity. Proliferation-like defects in the enamel become penetrated by connective tissue, fuse the germ at these points, and cause the enamel epithelium to invaginate. After mineralization has begun, the arrest is resolved and previously fused area follows the movements of the rest of the tooth. The degree of retardation and the depth of the invagination are thus functions of the size and number of the original epithelial defects.^{1,7,33}

Fusion occurs when some physical force or pressure brings about contact of two normally separated tooth germs. It occurs during the developmental stage of the teeth. When the contact occurs before the calcification stage the teeth unite and a single large tooth mass is produced. When the contact and union of the teeth occurs after the formation of the crowns incomplete fusion at the root level is formed.^{1,7}

Heredity may play a role in the occurrence of both gemination and fusion. Moody and Montgomeri¹⁷ observed a tendency to double teeth and complete fusion two deciduous incisors in three families. Fusion and/or

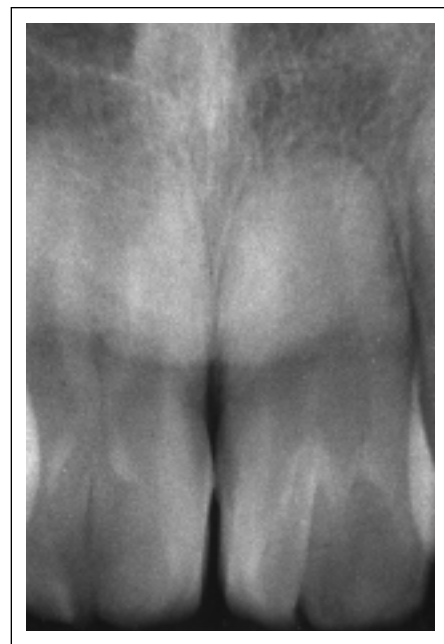


Figure 4. Periapical roentgenograms of the germinated and fused maxillary central incisors.

twin formation in region of mandibular deciduous central and lateral incisors was observed with only females involved. There was a sex limitation of an autosomal gene. Grahnen and Granath¹⁸ found identical twin girls and the brother with fused mandibular deciduous anterior teeth. The corresponding permanent tooth germs were absent. They were also missing on one or both sides in other siblings. Passarge and Bosman²⁰ found the condition in a father and his son and Schulze¹⁹ in sibs. However, the trait was observed in the lower arch. Atasu and Eryilmaz⁴⁷ noted that it was not overlooked that there might be similar factors affecting the development of both macrodontism and fusion of the central maxillary incisors. A recent report on fused maxillary central incisor teeth gives us evidence supporting the hereditary basis of the condition. Indeed, Yanikoglu and Kartal⁴⁹ have found a fused maxil-

Table 1. The digital type, palmar and plantar configural types and the total finger and summed palmar a-b ridge-counts of the patient.

| Fingers | | | | | TRC | Palmar formulae | Summed palmar a-b ridge-count | Plantar formulae |
|---------|----|-----|----|---|-----|-------------------------|-------------------------------|----------------------|
| V | IV | III | II | I | | | | |
| L | U | U | U | R | 134 | IV t ⁴ (1) | 84 | I i l l l e f p' z 4 |
| R | U | U | U | R | | III t ^b 4(3) | | I i l l e f z 4 |

lary lateral incisor in two sibs. Thus, they suggested that the trait might be at least hereditary. The pedigree of the present patient revealed that fusion in association with gemination might be a spontaneous character.

The dermatoglyphics of the patient presented here were somewhat different from that of previously reported by Atasu and Eryilmaz.⁴⁷ The authors have mentioned that the patient with synodontous central incisors had mainly whorls on the finger-tips, a high total finger ridge-count and III and H loops on the palms. But, the present patient had more ulnar loops on the finger-tips and a low total finger ridge-count. However, it should be noted that gemination in association with fusion could be considered a distinct character. Finally, it should be noted that the development of both skin and tooth begins at the same time and both of them are derived from the same layers during embryogenesis and at this time abnormal tooth development and unusual dermatoglyphic patterns may be expected.

REFERENCES

- Schulze C. Developmental abnormalities of the teeth and jaws. In Gorlin RJ Goldman HM (eds) Thomas Oral Pathology. St. Louis CV Mosby pp 183, 966. 1970.
- Shafer W. Hine M, Levy B. Developmental disturbances of oral and paraoral structures. A textbook of oral pathology (3rd edition). Philadelphia WB Saunders co. pp 35-37, 1974.
- Stewart RE, Prescott CH. Genetic aspects of anomalous tooth development. Oral facial genetics. St. Louis CV Mosby Co. pp 140-142, 1976.
- Kerr D, Ash M. Developmental disturbances. Oral Pathology (4th edition). Philadelphia. Lea and Febiger pp 65-67, 1978.
- Davis J, Law D, Lewis T. Anomalies of the dentition. An atlas of pedodontics (2nd edition) Philadelphia WB Saunders Co. pp 57-58, 1976.
- Stewart RE, Barbe TK, Troutman KC, Wei SHY. Pediatric Dentistry. Scientific foundations and clinical practice. St. Louis CV Mosby Co. 87-134. 1982.
- Tannenbaum K, Alling E. Anomalous tooth development. Oral Surg 16: 883-887. 1963.
- Levitax TC. Gemination, fusion, twinning and concrescence. J Dent Child 32: 93-100, 1965.
- Gersh RP, Isles B. Bilateral connation of primary molars: report of a case. J Dent Child 40: 39-41, 1973.
- Tagger M. Tooth gemination treated by endodontic therapy. J Endodont 1: 81, 1975.
- Levitas T. Gemination, fusion, twinning and concrescence (Abstract) J Endodont 2: 227, 1976.
- Stabholz A, Friedman S. Endodontic therapy of an unusual maxillary permanent first molar. J Endodont 9: 293-295, 1983.

- Rome WJ. Endodontic therapy involving an unusual case of gemination. J Endodon 10: 546-548, 1984.
- Brook AH, winter GB. Double teeth. A retrospective study of "geminated" and fused" teeth in children. Br Dent J 129: 123-130, 1970.
- Libfeld H, Stabholz A, Friedman S. Endodontic therapy of bilaterally geminated permanent maxillary central incisors. J Endodont 12: 214-216, 1986.
- Chen RI, Wang CC. Gemination of a maxillary premolar. Oral Surg Oral Med Oral Path 69: 556. 1990.
- Moody E, Montgomeri LB. Hereditary tendencies in tooth formation. J Am Dent Assoc 21: 1774-1776, 1934.
- Grahnen H, Granath LE. Numerical variations in primary dentition and their correlatton with the permament dentition. Odortol Rev 12: 348-357, 1961.
- Schulze C. Developmental abnormalities of the teeth and jaws. In Gorlin RI. Goldman HM (eds) Thomas Oral Pathology, St Louis CV Mosby, 96-183, 1970.
- Passange E, Bosman H. Fusion of lateral incisors as autosomal dominant trait Birth Defects Orig Art Ser VII: 194-195, 1971.
- Ellisdon PS, Marshall KF. Connation of maxillary incisors. Br Dent J 129: 16-21, 1970.
- Ravn JJ. Aplasia. supernumerary teeth and fused teeth in the primary dentition. An epidemiologic study. Scand J Dent Res 79: 1-6. 1971.
- Mofson ER. Congenital single incisor. Oral Surg 38: 490, 1974.
- Itkin AB, Barr GS. Comprehensive management of the double tooth: report of case. J Am Dent Assoc 90: 1269-1272, 1975.
- Mehlman ES. Management of totally fused central and lateral incisor with interuar resorption perforating the lateral aspects of the tooth. J Endodont 4: 189, 1978.
- Mader CL. Fusion of teeth. J Am Dent Assoc 98: 62-64, 1979.
- Sawyer M, Pekoff MD, Trott I. Endodontic therapy in an unusual case of fusion. I Endodont 6: 796, 1980.
- Jarvinen S, Lebtinen L, Milen A. Epidemiologic study of joined primary teeth in Finnish children. Community Dent Oral Epidemiol 8: 201, 1980.
- Eidelman E. Fusion of maxillary primary central and lateral incisors bilaterally. Pediatr Dent 3: 346-347, 1981.
- Grossman KE. Endodontics involving an unusual case of fusion. J Endodon 7: 40-41, 1981.
- Blaney T, Hartwell G, Bellizzi R. Endodontic management of a fused tooth: a case report. J Endodont 8: 227-230, 1982.
- Bazan MT. Fusion of maxillary incisors across the midline. Clinical report. Pediatr Dent 5: 220-221, 1983.
- Blank BS, Ogg RR, Levy AR. A fused central incisor. Periodontal considerations in comprehensive treatment. J Periodontol 56: 21-24, 1984.
- Morechaux SC. The treatment of fusion of maxillary central incisor and a supemumerary: report of a case. J Dent Child 52:196-199, 1984.
- Sinai HI, Lustbader S. A dual rooted maxillary central incisor. Endodont 10: 105-106, 1984.
- Hagman FT. Fused primary teeth: a documented familial report of case. J Dent Child 52: 459-460, 1985.

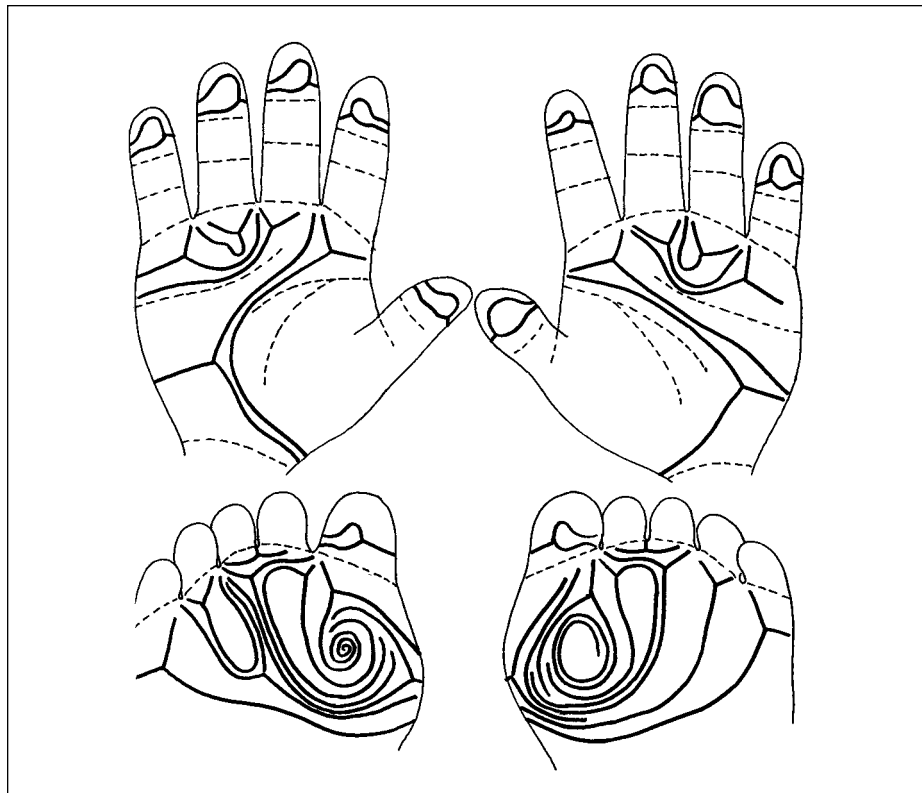


Figure 5. A 17-year-old male with enlarged tooth masses in the anterior of maxilla.

37. Ruprecht A, Betniji S, El. Neweishi E. Double teeth: the incidence of gemination and fusion. *J Pedodont* 9: 332-337, 1985.
38. Atkins CO, Mourino AP. Management of a supernumerary tooth fused to a permanent maxillary central incisor. *Oral Surg Oral Med Oral Path* 61: 146-148, 1986.
39. StilIwell KD, Coke IM. Bilateral fusion of the maxillary central incisors to supernumerary teeth: report case. *JADA* 112: 62-64, 1986.
40. Himelhoch DA. Separation of fused primary incisors: report of case. *J Dent Child* 55: 294-297, 1988.
41. Nik-Hussein NN. Bilateral symmetrical fusion of primary and permanent mandibular lateral incisors and canines. *J Pedodont* 13: 378-383, 1989.
42. Nik-Hussein NN. Bilateral symmetrical fusion of primary and permanent mandibular lateral incisors and canines. *J Pedodont* 13: 378-383, 1989.
43. Smith BE, Carnol B. Maxillary lateral incisor with two developmental grooves. *Oral Surg Oral Med Oral Path* 70: 523-525, 1990.
44. O'Carroll MK. Fusion and gemination in alternative dentitions. *Oral Surg Oral Med Oral Path* 69: 655, 1990.
45. Mangani F. Endodontic treatment of a 'peculiar' upper incisor (Abstract). *Giornale Italiano di Endodontia* 5: 106-108, 1991.
46. Acs G, Cozzi E, Pokala P. Bilateral double primary molars: case report 14: 115-116. 1992.
47. Atasu M, Eryilmax A. Synodontia between maxillary incisor and a supemumerary incisor teeth: a dental, genetic and dermatoglyphic study. *J Clin Pediatr Dent* 20:247-251, 1996.
48. Kayalibay H, Uzamis M, Akalin A. The treatment of a fusion between the maxillary central incisor and supemumerary tooth: report of a case. *J Clin Pediatr Dent* 20: 237-240, 1996.
49. Yantkoglu F, Karsal N. Endodontic treatment of a fused maxillary lateral incisor. *I Endodont* 24: 57-59, 1998.
50. Moore KL. *The developing human. Clinically oriented embryology.* WB Saunders Comp. Philadelphia, London, Toronto, 421-436, 1988.
51. Avery JK. Ed by Steele PF. *Essentials of oral histology and embryology,* Mosby. Year Book, 51-83, 1992.
52. Schaumann B, Alter M. *Dermatoglyphics in medical disorders.* Springer-Verlag. New York, Heidelberg, Berlin, 146-196, 1976.