

## Ferric sulfate as pulpotomy agent in primary teeth: twenty month clinical follow-up

Hamijeta Ibricevic\* / Qumasha Al-Jame\*\*

*Seventy primary molar teeth, carious exposed, symptom free, without any sign of root resorption in children aged from 3 to 6 years (main age 4.3yr) were treated with conventional pulpotomy procedures. Ferric sulfate 15.5% solution (applied for 15 second for 35 teeth) and formocresol solution (five minute procedure of Buckley's formula for next 35 teeth) have been used as pulpotomy agents. In both groups, pulp stumps were covered with zinc-oxide eugenol paste. Permanent restorations were stainless steel crowns. Clinical check up was every three-months and radiographic follow-up time was six and twenty months after treatment. Our results within this period revealed 100% clinical success rate in both groups. Radiographic success rate was in both groups 97.2%, while in 2.8% cases has shown internal root resorption. On the basis of these results, we can recommend ferric sulfate as a pulpotomy agent in primary teeth in substitution for formocresol at the moment.*

J Clin Pediatr Dent 24(4): 269-272, 2000

### INTRODUCTION

The most frequently performed dental procedure on primary molar teeth in the children under age six is pulpotomy.<sup>1</sup> Pulpotomy treatment includes applying a medicament over the residual radicular pulp tissue to promote healing and to allow normal tooth physiology to continue.<sup>2</sup>

According to Ranly,<sup>3</sup> pulpotomy therapy for primary teeth has developed along three lines: devitalization, which has been typified by formocresol and electrocautery, preservation, exemplified by glutaraldehyde and ferric sulfate, and regeneration, associated with calcium hydroxide, which is often not the recommended dressing for pulpotomies in primary dentition, because of a limited clinical success rate.<sup>4</sup>

The ideal pulpal dressing material is still not available. Formocresol is one of the most studied dental agents since its introduction in 1904.<sup>5</sup> In addition to that, there is a disagreement on its use in dentistry. Recently, the profession has been urged to reevaluate

the rationale underlying the use of formaldehyde in dentistry in light of accusations of its deleterious side effects.<sup>6</sup> Still the most popular pulpotomy agent among pediatric dentists and the standard by which all new modalities are compared, has remained five-minute formocresol protocol<sup>7,8</sup> with explanation that the state of current research on alternate medicaments are not sufficient to convince the majority of pediatric dentists that a satisfactory alternative has yet been developed.<sup>7</sup> Ferric sulfate has been proposed as pulpotomy agent on the basis of its action as a metal-protein clot at the surface of the pulp stump, thus acting as a barrier to the irritate components of the sub-base<sup>8</sup> as non-toxic.<sup>9</sup> This assumption has been demonstrated on animal models<sup>10,11</sup> as well as on human teeth.<sup>12-14</sup>

The present study has aimed to assess clinical and radiographic effects of 15.5% ferric sulfate compared to standard five-minute formocresol (full strength Buckley's formula) as pulpotomy agent on cariously exposed human primary twenty months after treatment.

### MATERIALS AND MEHTODS

Seventy children, divided into two equal groups of 24 male and 46 female, ranging in age from 3 to 6 with mean age 4.3yr were included in this study. They were regular patients for treatment of large carious lesions. The criteria for selection of the teeth were as proposed by Fuks:<sup>15</sup> (1) large carious lesion in otherwise restorable tooth, (2) no spontaneous pain, (3) at least two-thirds of the root length is still present, (4) no sign of internal or other kind root resorption, and (5) hemorrhage from amputated sites easy to control.

\* Ibricevic BDS, MS, PhD, Associate Professor of Pediatric Dentistry.

\*\* Qumasha Al-Jame BDS, MS, Chairman of Pediatric Dentistry Department, Al-Amiri Dental Center, Kuwait.

Send all correspondence to Dr. Hamijeta Ibricevic, P.O. Box. 472, Postal Code 15455 Dasman, Kuwait, Arabian Gulf.

Tel: 965 240 6306

Fax: 965 2449664

E-mail: Hamijeta@ncc.moc.kw

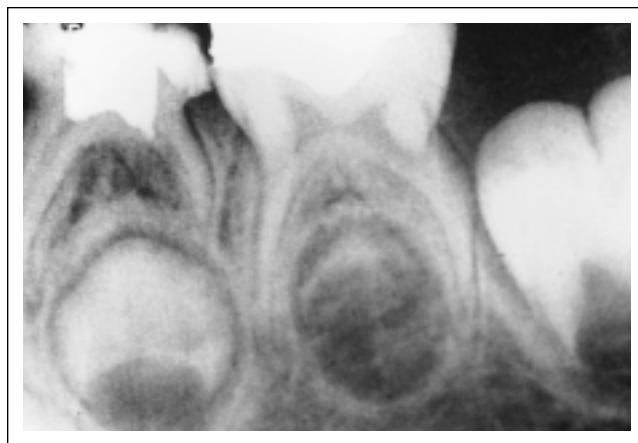
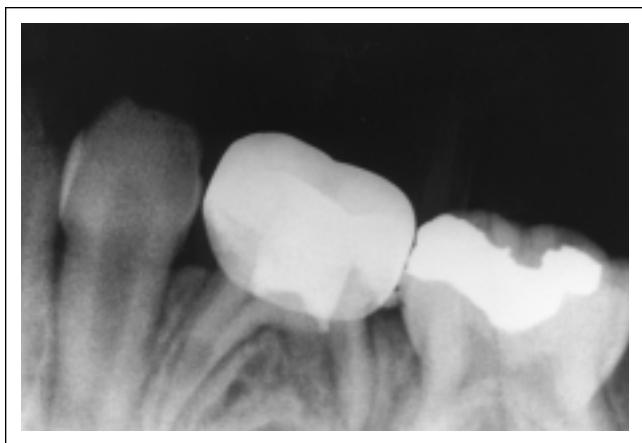


Figure 1 & 1a. Radiograph showing internal resorption in the mesial root in twenty months follow up time with ferric sulfate. 1a – radiograph of same tooth on the beginning procedure, immediately after pulpotomy.

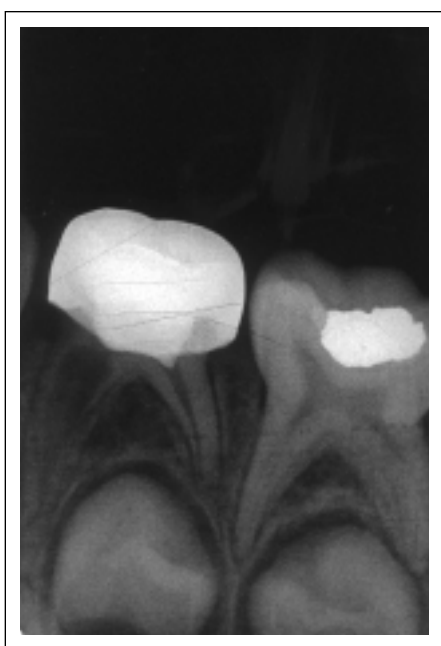

Figure 2. Radiograph showing internal resorption of root in formocresol group in twenty month follows up time.

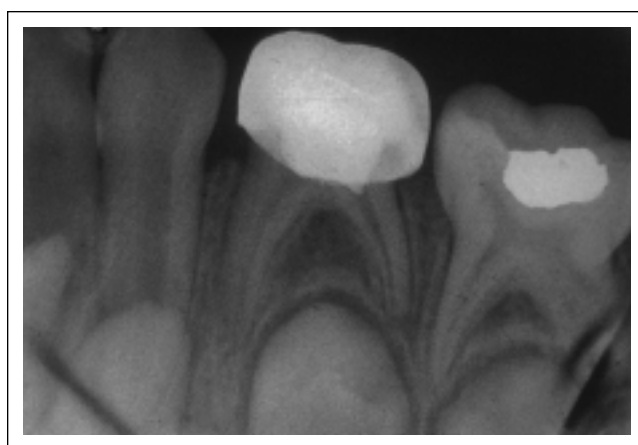


Figure 2a. Radiograph of same tooth at the day of pulpotomy.

Patients were randomly assigned to group I, (ferric sulfate treatment) and group II, (standard 5-minute formocresol treatment).

#### PULPOTOMY TECHNIQUE

Adequate anesthesia has been administered and rubber dam placed for every patient. All carious dentin has been removed before opening pulp chamber. Opening pulp chamber was done with fissure bur and amputation of the pulp with sterile round bur N = 300 (TS-RA Messenger Germany) in high-speed turbine. Amputated sites were rinsed with saline and dried with sterile cotton pellet.

In group I (35 teeth) after homeostasis of the amputated sites, 15.5% ferric sulfate ( $\text{Fe}_2(\text{SO}_4)_3$ ) in an aqueous vehicle, (Ultradent products) has been

applied for 15 second. The cavity was than washed with saline with aim to avoid all pieces of blood cloth formation. The cavity has been dried with sterile cotton pellet and the pulp stump covered with zinc-oxide-eugenol paste. Stainless still crowns (SSC) were placed as permanent restoration, except for very uncooperative children. In those cases, over the zinc oxide eugenol paste, IRM was placed for five days and then SSC was placed.

In-group II the pulpotomy agent was formocresol (original Buckley's formula for 5 minutes) with sub-base of zinc-oxide-eugenol paste and permanent restoration protocol was same.

Clinical follow-up was made every three months up to twenty months. The teeth were judged to be clinically successful, if they had no symptoms of pain or tenderness to percussion, swelling or fistulation.

Radiographic evaluation of treated teeth included follow-up of periodontal ligament space, and root status. Radiographs were taken immediately after the procedure, and six and twenty months later. Radiological success required normal periodontal ligament space, no

pathological internal or external root resorption and no intraradicular or periapical radiolucency.

## RESULTS

The treated teeth were examined clinically every three months up to twenty months after the pulpotomy. They have shown 100% clinical success rate in both groups. Radiographs showed one tooth in the formocresol group with internal root resorption (Figure 1) as well as one tooth in the ferric sulfate group. (Figure 2) It was 2.8% failure rate in the ferric sulfate group and 2.8% in formocresol group. Rest of the treated teeth had normal radiographic findings.

## DISCUSSION

The use of ferric sulfate in this study was found to produce a similar effect as formocresol in primary teeth as pulpotomy agents, measured by clinical and radiographic standards. This is in accordance with previous findings of Prabhy,<sup>11</sup> and also corroborates the findings of Lewis,<sup>6</sup> that ferric sulfate is able to achieve the same goal as formocresol which possess toxic side effects.

Ideal pulpotomy agents should leave the radicular pulp vital, healthy and completely enclosed within an odontoblast lined dentin chamber.<sup>8</sup> Only in this way could early root resorption be preserved and tooth enter into exfoliative process at the appropriate time. For that reason, the main objective of this treatment today is to maintain vitality of the majority of the radicular pulp.<sup>15</sup>

The potential risk for internal resorption is increased in the teeth where predentin is lacking.<sup>10</sup> Formocresol as well as ferric sulfate do not have ability to induce new dentin deposition.

The ideal pulpotomy agent is not available yet. Systemic and local toxic side effects of formocresol as evident though much research proved, that replacement of formocresol has become imperative.<sup>10</sup> Ferric sulfate has been used on assumption that it might prevent problems originating from clot formation, thereby reducing chances for chronic inflammation and internal resorption without the toxic side effects of formocresol.<sup>10</sup>

In the present study, one tooth treated with ferric sulfate has revealed internal root resorption after twenty months, as well as one with formocresol. In three years follow-up study by Fuks<sup>10</sup> on 15.5% ferric sulfate applied for 15 second, 7.2% of cases presented internal resorption compared with 5.4% in the group with diluted formocresol. Inter-radicular resorption was observed in two teeth treated with ferric sulfate and three of formocresol group.

Ferric sulfate, used as 1% feraculum solution gives a 100% clinical success rate as well as a histologically, during nine months. Radicular pulp was seen normal, however, not a single case of internal resorption, was seen in Prabhy<sup>12</sup> study.

In other histological studies on animal models Fuks,<sup>10</sup> on baboons' teeth, the success rate was unfavor-

able clinical results. Only 60% of treated pulps were shown normal after 8 weeks. Degree of inflammation in the groups treated with ferric sulfate was not lower than the group treated with formocresol in animal studies conducted by Olga.<sup>11</sup>

One explanation for this discrepancy in histological and clinical findings was that chronic inflammation of the pulp without periapical abscess formation maybe clinically and radiographically normal.<sup>10</sup>

The high success rate in this study of 97.2% in both groups, we suppose to be as a result of very carefully assessment of status of remaining radicular pulp after amputation, especially regarding bleeding. Despite the high correlation demonstrated between the type of bleeding and indication for pulpotomy, there is no means of precisely determining clinically the status of the pulp tissue in the radicular part. Existing opinion though, states,<sup>10</sup> that the inability of clinicians to determine the degree and extent of pulpal inflammations is one of the major causes of unpredictability of pulp capping,<sup>16</sup> as well as pulpotomy. Most probably 2.8% failure in both treated groups in this study was the result of wrong determination of status of remaining pulpal tissue.

As Bimstein<sup>2</sup> mentioned, systemic toxic effects caused by formocresol can happen in general anesthesia cases in which several pulpotomies may be done during the same appointment. The number of pulpotomies done under general anesthesia under age five was 3.5 in our previous study.<sup>17</sup> The replacement of formocresol with ferric sulfate as an advantage, in this general anesthesia cases.

Another advantage of ferric sulfate over formocresol regarding time of manipulation, 15 seconds, required manipulation time for ferric sulfate compared to 5 minutes of formocresol required time with the same success rate, is evidence massive enough for consideration in replacement of formocresol with ferric sulfate.

The main source of assessment of pulpotomy agents comes from clinical observations and experience.<sup>3</sup> The mechanism of action remains unclear. Lack of knowledge of pulpal physiology of primary teeth is most probably one of the main reasons why all dental procedures regarding dental pulp have remained controversial. Advances were made in the field of pulpal physiology in last decades and promises to change our approach to pulpal therapy.<sup>18</sup>

Understanding of the role of TGF-beta in dental tissue repair through either reparative or reactionary dentinogenesis will allow the exploitation for new approaches in the treatment of dental diseases.<sup>19</sup> The family of bone morphogenic proteins with inductive properties suggests a therapeutic applications in a range of clinical demands.<sup>20</sup> These substances are still far from clinical practice at this time we must still deal with chemicals and rely on clinical observations and experience.

## CONCLUSION

Ferric sulfate as a pulpotomy agent was able to produce the same effect as formocresol on primary human molar teeth in this study. As nontoxic and easy to manipulate, ferric sulfate can be recommended as a pulpotomy agent for replacement of formocresol. Additional studies are required to evaluate role of ferric sulfate in pulpotomy procedure. Longer observation periods are also recommended.

## REFERENCES

1. Nainar SM. Profile of primary teeth with pulpal involvement secondary to caries. *J Dent Child* 65: 57-9, 1998.
2. Bimstein E. Pulpotomy treatment in primary teeth. *The Compendium* 6: 8, 586-591, 1985.
3. Ranly DM. Pulpotomy therapy in primary teeth: new modalities for old rationales. *Pediatr Dent* 16: 403-409, 1994.
4. Gruythuysen RJM, Weerheijm KI. Calcium hydroxide pulpotomy with a light-cured cavity-sealing material after two years. *J Dent Child* 64: 251-253, 1997.
5. Alacam A. Long term effects of primary teeth pulpotomies with formocresol, glutaraldehyde-calcium hydroxide and glutaraldehyde-zinc oxide eugenol on succudaneous teeth. *Pediatr Dent* 13: 307-312, 1989.
6. Lewis B. Formaldehyde in dentistry: a review for the millennium. *Pediatr Dent* 22: 167-177, 1998.
7. Avram DC, Pulver F. Pulpotomy medicaments for vital primary teeth. *J Dent Child* 56: 426-434, 1989.
8. Ranly DM, Garcia-Gody F. Reviewing pulp treatment for primary teeth. *JADA* 122: 83-86, 1991.
9. Amazon KR, Ywlin AM. Furrugination caused by Monsel's solution. *Clinical observations. Am J Dermatopath* 2: 197-228 1980.
10. Fuks AB, Eidelman E, Cleaton-Jones, Michaeli Y. Pulp response to ferric sulfate, diluted formocresol and IRM in pulpotomized primary baboon teeth. *J Dent Child* 64: 254-259, 1997.
11. Coates O, Boj JR, Canalda C, Carreras M. Pulpal tissue reaction to formocresol vs. ferric sulfate in pulpotomized rat teeth. *Pediatr Dent* 21: 247-253, 1997.
12. Prabhu NT, Munshi AK. Clinical, radiographic and histological observations of the radicular pulp following "feracrylum" pulpotomy. *J Clin Pediatr Dent* 21: 151-156, 1997.
13. Fuks AB, Holan G, Davis JM, Eidelman E. Ferric sulfate versus dilute formocresol in pulpotomized primary molars: long-term follow-up. *Pediatr Dent* 19: 327-30, 1997.
14. Fei AL, Udin RD, Johnson R. A clinical study of ferric sulfate as a pulpotomy agent in primary teeth. *Peditr Dent* 13: 327-32, 1991.
15. Fuks AB, Bimstein E, Guelman-Mklein H. Assessment of a 2 percent buffered glutaraldehyde solution in pulpotomized primary teeth of schoolchildren. *J Dent Child* 57: 371-375, 1990.
16. Levin LG. Pulpal regeneration. *Practical Periodontics & Aesthetics* 10: 621-4, 1998.
17. Ibricevic H, Mirkov M, Al-Jame Q, Al-Gaoud O. Pediatric dental treatment under general anesthesia at Al-Amiri hospital. *The 8th Kuwait Dental Association Conference. Abstract book* 35-36.
18. Ketley CE, Goodman RJ. Formocresol toxicity: is there a suitable alternative for pulpotomy of primary molars? *J Ped Dent* 2: 67-72, 1991.
19. Wozney MJ. The bone morphogenic protein family: multifunctional cellular regulators in the embryo and adult. *Eur J Oral Sci* 106 (suppl 1): 160-66, 1998.
20. Smith JA, Matthews BJ, Hall CR. Transforming growth factor Beta 1 (TGF-beta1) in dentine matrix. Ligand activation and receptor expression. *Eur J Oral Sci* 106 (suppl 1) 179-84, 1998.