

ORIGINAL RESEARCH

Fractal dimension analysis of mandibular trabecular bone in severely infraoccluded primary molars: a retrospective case-control study

Ecem Elif Çege^{1,*}, Yasemin Çamlıbel², Neşe Akal³¹Department of Pediatric Dentistry,
Faculty of Dentistry, Karabük University,
78050 Karabük, Turkey²Department of Oral and Maxillofacial
Radiology, Faculty of Dentistry, Ondokuz
Mayıs University, 55270 Samsun, Turkey³Department of Pediatric Dentistry,
Faculty of Dentistry, Gazi University,
06490 Ankara, Turkey***Correspondence**elifcege@karabuk.edu.tr
(Ecem Elif Çege)**Abstract**

Background: Infraocclusion is a condition where the occlusal surface of a tooth lies below the occlusal plane or the level of adjacent teeth. Etiological factors, such as ankylosis and increased masticatory forces, can directly affect alveolar bone development and resorption processes, potentially leading to microstructural alterations in the region. These changes can affect the density and organisation of mandibular trabecular bone. Fractal dimension (FD) analysis is a promising method for evaluating such structural changes. This study aimed to investigate the effect of severe infraocclusion in mandibular primary molars on trabecular bone structure using FD analysis of panoramic radiographs. **Methods:** This retrospective study included 72 children aged 7–12 years: 36 with severe infraocclusion and 36 age- and gender-matched controls without infraocclusion. Panoramic radiographs obtained at the Faculty of Dentistry, Gazi University between January 2020 and December 2024 were evaluated. Infraocclusions were classified according to the Brearley and McKibben system. FD values were calculated using ImageJ software. Statistical analyses were performed using SPSS version 27. Due to non-normal data distribution, appropriate statistical tests were applied. Chi-square test was used for gender and germ comparisons; Mann-Whitney U test for age and germ-related FD values; and Independent Samples *T*-test for FD comparisons between groups and genders. A *p*-value < 0.05 was considered significant. **Results:** A significant difference in FD values between groups only in the mandibular angulus region (*p* < 0.05), with higher values found in the study group. No gender-related differences were observed (*p* > 0.05). Within the study group, a significant difference in FD values was observed in the condylar region according to the presence of the permanent tooth germ, with higher values recorded when the germ was present (*p* < 0.05). **Conclusions:** Infraocclusion might be associated with localised changes in the mandibular trabecular bone. FD analysis can provide valuable insight into its etiology and assist in clinical treatment planning. Further studies using with larger samples and periapical radiographs are recommended.

Keywords

Fractal dimension analysis; Infraocclusion; Mandible; Primary molar; Retrospective study

1. Introduction

Infraocclusion is defined as the condition in which the occlusal surface of a tooth lies below the occlusal surfaces of adjacent teeth or the occlusal plane. It is most commonly observed in the mandible, typically bilateral, and may involve multiple primary molars simultaneously [1]. This condition presents with various clinical and radiographic features, including abnormal root resorption of the affected tooth and changes in the surrounding alveolar bone. Clinically, ankylosed teeth may appear submerged relative to adjacent teeth, exhibit a characteristic thud-like percussion sound, and show reduced

or absent physiological mobility [2].

Infraocclusion situation is often associated with ankylosis and is radiographically characterised by loss of periodontal ligament space. Local metabolic disorders, periapical infections, excessive occlusal forces and genetic predisposition may contribute to ankylosis development in primary molars [3]. Histological studies of infraoccluded teeth have demonstrated ankylosis in most affected cases [4]. In a similar study, Kurol and Magnusson surgically extracted infraoccluded teeth for histological evaluation and performed bone biopsies from the buccal bone and the bifurcation region [4]. Although all bone samples showed normal histological appearances, the

buccal alveolar bone crest was notably thicker compared to the control group [4]. Another etiological factor associated with infraocclusion is the congenital absence of premolars. This condition has been reported more frequently in patients with infraoccluded primary molars than in the general population [5]. In a retrospective study by Lai *et al.* [6], infraocclusion was observed in 65.7% of primary molars without permanent tooth germs, whereas the overall prevalence was 1.5% in the general population. Similarly, Bezgin *et al.* [7] reported a prevalence of 20% infraocclusion in mandibular primary molars among patients with congenitally missing second premolars. In addition, increasing masticatory forces with age have been associated with a higher risk of infraocclusion in the second primary molars [8, 9].

Fractal dimension (FD) analysis is a method based on the mathematical modelling of complex and irregular structures. By calculating the “fractal dimension” of an object or tissue, this analysis quantitatively evaluates and quantifies its complexity, irregularity or structural variability [10]. In medicine and dentistry, FD analysis objectively assesses structural changes, allowing for the early detection of pathological changes in tissues and organs [11]. It has proven to be effective in evaluating biological tissues or bone structures where conventional measurements may be inadequate. A significant advantage of this method is its ability to uncover the hidden complexity of tissues compared to traditional imaging techniques, providing quantitative data non-invasively [12].

In dentistry, FD analysis has been employed across various fields, including evaluation of bone loss [13], periodontal disease [14, 15], diagnosis of temporomandibular joint disorders [16], implant surface characteristics [17], assessment of endodontic lesions healing after root canal treatment [18], detection of dental caries [19], staging, grading, and prognostic assessment in histological specimens of oral squamous cell carcinoma [20], and the diagnosis of osteoporosis [10]. However, the primary application of FD analysis in dentistry remains the evaluation of jawbone morphology and its potential structural changes over time [21]. For instance, FD values of bone tissue obtained from dental radiographs can be utilized to monitor periodontal disease progression. Irregularities in bone architecture or trabecular bone degeneration can be identified through FD analysis [12].

In infraocclusion cases, factors such as ankylosis and increased masticatory forces may directly influence alveolar bone development and resorption, leading to microstructural changes in the affected regions. These alterations could result in significant differences in mandibular trabecular bone density and organization [9]. In this context, FD analysis represents a valuable tool for examining the effects of infraocclusion on bone architecture [22, 23].

The aim of this study is to evaluate the impact of severe infraocclusion on mandibular trabecular bone by analyzing panoramic radiographs of children with and without severe infraocclusion in mandibular primary molars. The analysis was performed using the FD analysis method. To the best of our knowledge, this is one of the first studies to analyze mandibular trabecular bone alterations in children with severe infraocclusion via FD analysis. In addition, the influence of permanent tooth germ presence or congenital absence on

trabecular bone density was evaluated to gain further insight into developmental effects on bone architecture within this specific pediatric population. The null hypothesis of the study was that the structural characteristics of trabecular bone do not differ between cases with and without severe infraocclusion.

2. Materials and methods

2.1 Patient selection and data collection

In this retrospective case-control study, digital panoramic radiographs of healthy children aged 7–12 years who presented to the Department of Paediatric Dentistry, Faculty of Dentistry, Gazi University between January 2020 and December 2024 were evaluated.

2.1.1 Sample size

In the main hypotheses of the research, it is planned to investigate the differences between independent groups. Similar studies that can be used in sample size calculation were examined and the sample size calculation that gives the highest number according to the statistical methods to be applied in line with the main hypotheses was taken into consideration. In this study, using the “G.Power-3.1.9.2” programme (Heinrich Heine University, Düsseldorf, NRW, Germany) [24], at 95% confidence level ($\alpha = 0.05$), the standardised effect size was calculated as 0.9805 based on a previous study by Gulec *et al.* [25]; which evaluated continuous numerical data (means) between two groups. Accordingly, the minimum required sample size for each group was determined as 36 with a theoretical power of 0.80.

2.1.2 Study groups and randomization

All panoramic images were digitally obtained from the Picture Archiving and Communication System (PACS) integrated into the Patient Information Management System of Gazi University Faculty of Dentistry. Among 8743 panoramic radiographs screened, 36 patients with severe infraocclusion in their right mandibular second primary molars, meeting all inclusion and exclusion criteria, were selected for FD analysis. In total, 72 participants were included in this study, comprising 36 children (22 males, 14 females) diagnosed with severe infraocclusion and 36 healthy age- and gender-matched controls (20 males, 16 females) without infraocclusion. The control group was selected from the same population pool as the study group. Specifically, panoramic radiographs of 60 eligible children were sequentially numbered from 1 to 60 and recorded. Subsequently, 36 subjects were randomly chosen using the [randomizer.org](https://www.randomizer.org) tool to constitute the control group. The mean age was 9.86 ± 1.46 years in the study group and 8.64 ± 1.20 years in the control group.

Ethical approval was granted by the Gazi University Ethics Committee on 18.02.2025 (decision no: E-77082166-604.01-1178259).

2.2 Inclusion and exclusion criteria

The inclusion criteria:

1. Digital panoramic radiographs of healthy children aged between 7 and 12 years,

2. Radiographs with adequate image quality to allow diagnostic evaluation of the entire mandible,

3. Radiographs demonstrating severe infraocclusion of the right mandibular second primary molars, classified according to Brearley and McKibben's established criteria [26] (Fig. 1, Ref. [27]).

The exclusion criteria:

1. Presence of systemic diseases,
2. History of orthodontic or orthopedic treatment,
3. Presence of impacted teeth, cysts, tumors, craniofacial anomalies, or history of trauma/fracture involving the mandible or maxilla,
4. Pathological root resorption of the second primary molars,
5. Poor image quality due to horizontal or vertical distortion, metal or motion artifacts,
6. Inability to clearly visualize the mental foramen or regions of interest (ROI),
7. Superimposition of surrounding anatomical structures that compromised image interpretation.

2.3 Obtaining and evaluation of radiographic findings

All panoramic radiographs were obtained using the same panoramic imaging unit (Orthophos XG 5, Sirona, Bensheim, HE, Germany), set at 62 kVp, 8 mA, 14 seconds exposure time, and a magnification factor of 1.33, at the Department of Oral and Maxillofacial Radiology, Gazi University Faculty of Dentistry. Patient positioning during image acquisition followed the manufacturer's standardized instructions.

Radiographs of patients with severely infraoccluded mandibular second primary molars, classified according to Brearley and McKibben's criteria [26] (Fig. 1), and an equal number of control radiographs (without infraocclusion) were digitally recorded for analysis. Additionally, the presence or absence of permanent tooth germs beneath the infraoccluded primary molars was noted, evaluated to determine potential impacts on the mandibular trabecular bone structure.

The classification of Brearley and McKibben [26] lists infraocclusion as:

Mild-the occlusal surface lies approximately 1 mm below the occlusal plane;

Moderate-the occlusal surface is located at approximately the same level as the interproximal contact point of one or both of the adjacent tooth surfaces; or

Severe-the occlusal surface at or below the interproximal gingival level of adjacent teeth.

2.4 Fractal dimension analysis

Digitally recorded panoramic images were transferred to ImageJ 1.8v software (National Institutes of Health, Bethesda, MD, USA) by an experienced oral and maxillofacial radiologist. Three anatomical locations were selected on each image for FD analysis, defining a 30×30 pixel Region of Interest (ROI) for each site (Fig. 2). To ensure standardization, the right side of the mandible was used in all cases, and ROIs were carefully positioned to exclude teeth, cortical bone, and the mental foramen. These points included:

A 30×30 pixel area at the geometric centre of the condyle (Fig. 2A),

A 30×30 pixel area at the geometric center of the mandibular angle (Fig. 2B) and,

A 30×30 pixel area in the mandibular molar region above the mental foramen (Fig. 2C).

FD analysis was conducted using the box-counting method, following the image processing protocol proposed by White and Rudolph [28]. To evaluate intra-observer reliability, the analyses were repeated after a four-week interval. A detailed description of each step, including the processing of 30×30 pixel ROIs from different mandibular regions, is provided in the caption of Fig. 3.

For FD calculation, the "Fractal Box Counter" function under the "Analyze" menu was utilized. Each image is divided into squares of 2, 3, 4, 6, 8, 12, 16, 32 and 64 pixels. For each box size, the number of boxes containing trabecular structures and the total number of boxes are computed. A logarithmic graph is plotted based on these values, with the slope of the best-fit line representing the FD value (Fig. 4). This graph is expressed by the FD value "D" calculated from the slope of the line that best fits the points obtained from the logarithmic scale graph of the values.

FD values of trabecular bone calculated via the box-counting method are expected to fall between 1 and 2. The FD value of alveolar bone typically lies within this range, indicating that the bone exhibits fractal geometry. Values closer to 2 represent a more complex bone microarchitecture, whereas values approaching 1 indicate simpler, more porous structures [29]. In this context, when FD values obtained in the study are compared between the research and control groups, the presence of a statistically significant difference may indicate notable variations in trabecular complexity and bone density. The use of FD analysis in evaluating bone microarchitecture thus offers an objective method to detect potential structural differences between the groups.

2.5 Statistical analysis

All analyses were performed using IBM SPSS Statistics version 27 (version 27.0, IBM corp., Armonk, NY, USA). Descriptive statistics (frequency, percentage, mean, standard deviation, median, minimum and maximum) were reported for the data. The assumption of normality was assessed using the Shapiro-Wilk test, and homogeneity of variances was evaluated using Levene's test. Since the data did not show a normal distribution, non-parametric tests were applied where appropriate.

Pearson's Chi-square test was used to compare gender and the presence of tooth germs between groups. The Mann-Whitney U test was used to compare age and to evaluate FD values in relation to germ presence within groups. Independent Samples *T*-test was used to compare FD values between study and control groups, as well as to assess differences by gender. A *p*-value < 0.05 was considered statistically significant.

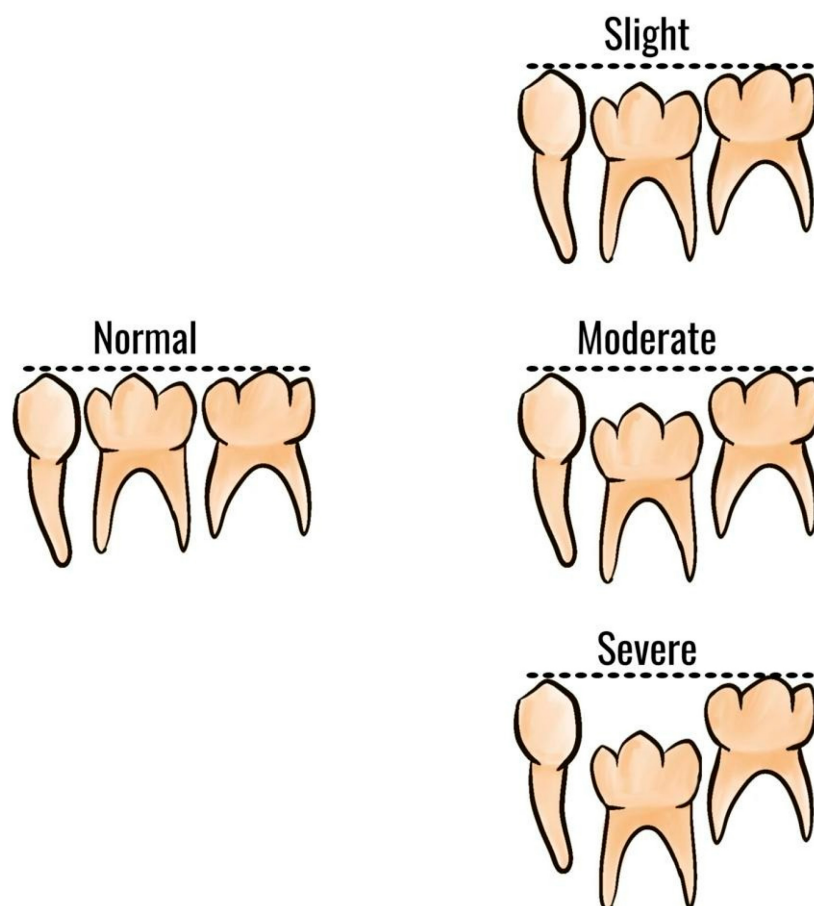


FIGURE 1. Classification of infraocclusion severity according to Brearley and McKibben [27].

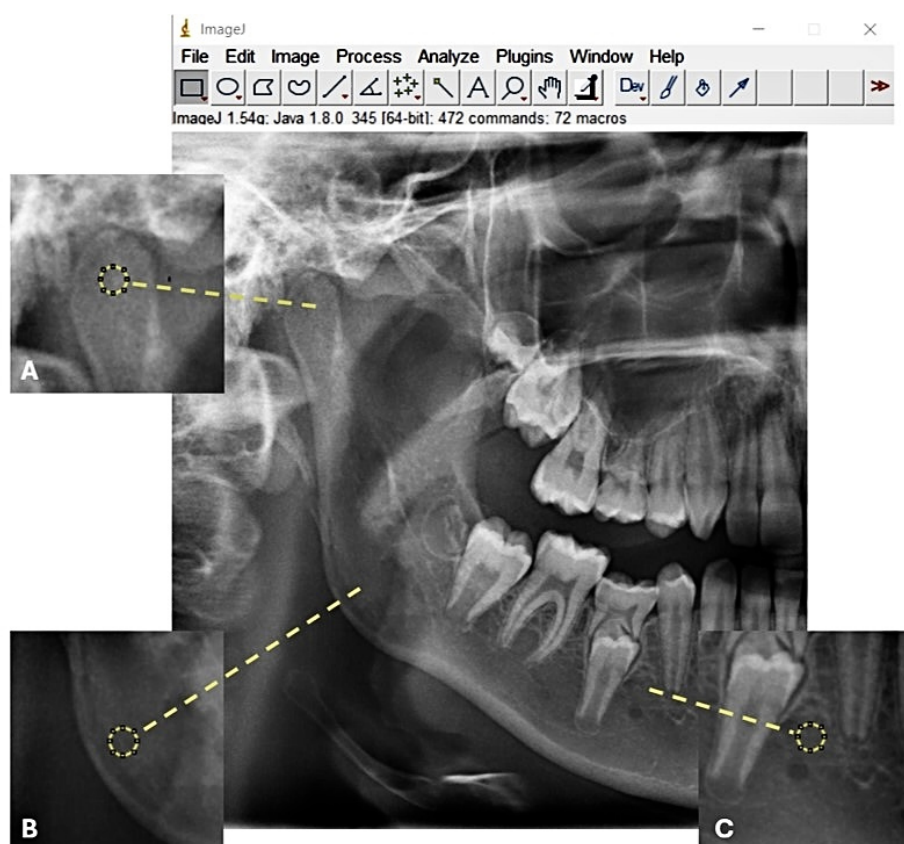


FIGURE 2. ROIs: region of interests. (A) ROI-1: Mandibular condyle. (B) ROI-2: Centre of mandibular angle. (C) ROI-3: Mandibular molar area.




FIGURE 3. Image processing steps for fractal analysis. (A) Cropped grayscale image. (B) Duplicated image. (C) A Gaussian blur filter (sigma = 35 pixels) is applied to minimize brightness variations caused by overlapping soft tissues and differences in bone thickness. (D) Subtracted image to enhance edges. (E) Image with added intensity (128) for normalization. (F) Binarized (black-and-white) image. (G) Eroded image for noise reduction. (H) Dilated image to enhance structures. (I) Inverted binary image for better outline visibility. (J) Skeletonized image for structural simplification.

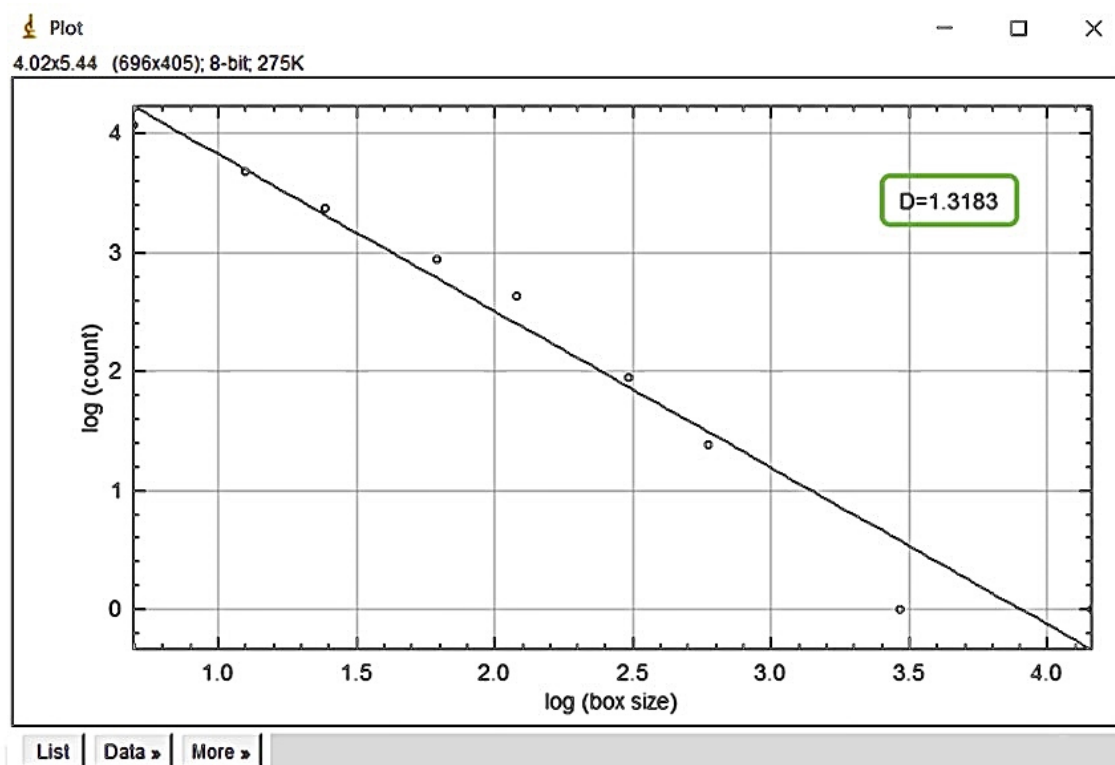


FIGURE 4. A plotted logarithmic graph, where the best graphical fit represents the FD value.

3. Results

This section presents an evaluation of potential differences in FD values between ROIs in the study and control groups, along with the possible effects of variables such as gender and the presence of permanent tooth germs on FD measurements.

Pearson's chi-square test was used to compare gender distribution and tooth germ presence between the groups. While there was no statistically significant difference in gender distribution ($p = 0.633$), a significant difference was identified in tooth germ presence ($p = 0.041$), with germ absence more

frequently observed in the study group (Table 1).

The age distribution between the study groups was compared using the Mann Whitney U test, as shown in Table 2.

Intraclass correlation coefficient (ICC) tests were conducted to evaluate the consistency of repeated measurements of the same variables. The analysis showed that the ICC values ranged from 0.951 to 0.983. As all values exceeded the minimum acceptable threshold of 0.700, the reliability of the measurements was considered to be statistically significant, high and highly consistent ($p < 0.05$) (Table 3).

Both the Mann-Whitney U test and the Independent Samples

TABLE 1. Distribution of gender and tooth germ presence according to groups.

	Study Group		Control Group		Total		Test Statistic	<i>p</i>
	n	%	n	%	n	%		
Gender								
Female	14	38.9	16	44.4	30	41.7	0.229	0.633
Male	22	61.1	20	55.6	42	58.3		
Tooth Germ								
Present	28	77.8	34	94.4	62	86.1	4.181	0.041*
Absent	8	22.2	2	5.6	10	13.9		

* $p < 0.05$ and Pearson's Chi-square test.

TABLE 2. Age distribution according to groups.

	Study Group		Control Group	
	Min.–Max.	Mean \pm SD (Median)	Min.–Max.	Mean \pm SD (Median)
Age	8–12	9.86 \pm 1.46 (9.5)	7–12	8.64 \pm 1.20 (8)

Mann-Whitney *U* test. Min: Minimum; Max: Maximum; SD: Standard deviation.

TABLE 3. Test-retest for measurements.

	Study Group		Control Group	
	ICC	<i>p</i>	ICC	<i>p</i>
Condyle (ROI-1)	0.955	<0.001*	0.958	<0.001*
Angle (ROI-2)	0.956	<0.001*	0.983	<0.001*
Molar (ROI-3)	0.951	<0.001*	0.973	<0.001*

* $p < 0.05$. ICC: Intraclass Correlation Coefficient; ROI: regions of interest.

T-test were utilized to compare FD values between the study and control groups. A statistically significant difference was detected in the mandibular angle region (ROI-2), where the study group exhibited higher FD values ($p = 0.004$). No significant differences were observed in the condyle (ROI-1) and molar (ROI-3) regions ($p > 0.05$) (Table 4).

Independent Samples *T*-test and Mann-Whitney *U* tests assessed the influence of gender on FD values within each group. No statistically significant gender-based differences were found in any of evaluated regions ($p > 0.05$) (Table 5).

The Mann-Whitney *U* test evaluated FD values based on the presence of tooth germs within each group. A statistically significant difference was found in the condyle region of the study group ($p = 0.008$), with higher FD values noted in individuals possessing tooth germs. No significant differences were identified in other regions or within the control group ($p > 0.05$) (Table 6).

4. Discussion

The etiology of infraocclusion remains unclear [3, 4]. Infraoccluded teeth show radiographic features such as pathological root resorption and changes in surrounding bone structures [23]. Fractal dimension (FD) analysis, provides objective and quantitative assessment of bone structural changes, may clarify morphological characteristics of trabecular bone around infraoccluded primary molars and potentially elucidate the etiology of infraocclusion. However, research examining the

relationship between infraocclusion and FD analysis remains limited [22, 23].

The present study, FD values from 36 mandibular second primary molars with infraocclusion in patients aged 7–12 were compared with age matched controls without infraocclusion. In all cases, the right side of the mandible was consistently selected for standardization. FD analysis was performed using the box-counting method according to the image processing protocol proposed by White and Rudolph [28]. Unlike previous studies reported in the literature on this topic, three different ROIs were defined and the measurements were evaluated separately. In this study, the condyle, mandibular angle, and molar regions were selected for fractal analysis in accordance with previous studies in the literature [25, 30]. These regions were selected based on their functional and developmental importance. The condyle and angle regions are known as active growth and remodeling areas during childhood and adolescence. Additionally, mandibular angle serving as the masseter muscle attachment site, experiencing significant masticatory activity [31]. The molar region, on the other hand, is directly affected by occlusal forces. These regions are thus considered suitable for assessing changes in trabecular bone structure potentially influenced by infraocclusion. Moreover, it has been emphasized in studies aiming to evaluate trabecular bone structure that dental structures should not be included within the ROI boundaries in order to avoid distortion of the fractal dimension values [25].

Our findings indicate a significant difference exclusively

TABLE 4. Distribution and comparison of measurements by groups.

	Study Group		Control Group		Test Statistic	<i>p</i>
	Min.–Max.	Mean \pm SD (Median)	Min.–Max.	Mean \pm SD (Median)		
Condyle (ROI-1)	1.08–1.43	1.28 \pm 0.09 (1.3)	1.01–1.4	1.28 \pm 0.10 (1.32)	–0.310	0.757
Angle (ROI-2)	1.05–1.42	1.31 \pm 0.10 (1.35)	1.04–1.4	1.25 \pm 0.10 (1.28)	–2.844	0.004*
Molar (ROI-3)	1.1–1.42	1.28 \pm 0.08 (1.28)	1.06–1.39	1.25 \pm 0.10 (1.26)	1.588 [‡]	0.117

* $p < 0.05$ and [‡]Independent Samples *T*-test. ROI: regions of interest; Min: Minimum; Max: Maximum; SD: Standard deviation.

TABLE 5. Distribution of measurements by gender within each group.

		Min.–Max.	Mean \pm SD (Median)	Test Statistic	p
Condyle (ROI-1)					
Study Group	Female	1.18–1.41	1.30 \pm 0.07 (1.30)	1.110	0.275
	Male	1.08–1.43	1.27 \pm 0.10 (1.30)		
Control Group	Female	1.01–1.37	1.29 \pm 0.09 (1.34)	−0.382 [†]	0.718
	Male	1.05–1.40	1.28 \pm 0.10 (1.32)		
Angle (ROI-2)					
Study Group	Female	1.20–1.41	1.33 \pm 0.06 (1.36)	−0.584 [†]	0.575
	Male	1.05–1.42	1.29 \pm 0.11 (1.33)		
Control Group	Female	1.10–1.37	1.26 \pm 0.08 (1.28)	−0.732	0.479
	Male	1.04–1.40	1.23 \pm 0.11 (1.27)		
Molar (ROI-3)					
Study Group	Female	1.19–1.42	1.29 \pm 0.07 (1.30)	1.384	0.704
	Male	1.10–1.42	1.28 \pm 0.09 (1.27)		
Control Group	Female	1.12–1.39	1.27 \pm 0.09 (1.29)	1.154	0.256
	Male	1.06–1.39	1.23 \pm 0.10 (1.22)		

[‡]Mann Whitney *U* test. ROI: regions of interest; Min: Minimum; Max: Maximum; SD: Standard deviation.

TABLE 6. Distribution of measurements by tooth germ presence within each group.

		Tooth Germ	Min.–Max.	Mean ± SD (Median)	Test Statistic	<i>p</i>
Condyle (ROI-1)						
Study Group	Present	1.08–1.43	1.30 ± 0.09 (1.31)	−2.587	0.008*	
	Absent	1.16–1.30	1.22 ± 0.06 (1.21)			
Control Group	Present	1.01–1.40	1.28 ± 0.10 (1.32)	−0.276	0.813	
	Absent	1.32–1.34	1.33 ± 0.01 (1.33)			
Angle (ROI-2)						
Study Group	Present	1.05–1.41	1.31 ± 0.09 (1.33)	−0.228	0.837	
	Absent	1.13–1.42	1.29 ± 0.12 (1.36)			
Control Group	Present	1.04–1.40	1.25 ± 0.10 (1.28)	−0.760	0.495	
	Absent	1.13–1.28	1.20 ± 0.10 (1.20)			
Molar (ROI-3)						
Study Group	Present	1.10–1.42	1.28 ± 0.08 (1.27)	−1.142	0.267	
	Absent	1.19–1.39	1.31 ± 0.08 (1.34)			
Control Group	Present	1.06–1.39	1.25 ± 0.10 (1.27)	−0.622	0.578	
	Absent	1.19–1.22	1.21 ± 0.02 (1.21)			

* $p < 0.05$. ROI: regions of interest; Min: Minimum; Max: Maximum; SD: Standard deviation.

in the mandibular angle region, potentially attributed to increased masticatory forces as a compensatory mechanism due to occlusal imbalance from infraocclusion. Furthermore, as the study population consisted of individuals in the mixed dentition period, anatomical and developmental variations may be more pronounced in the molar region and around the mental foramen, whereas the angulus region offers a relatively more stable structure. Furthermore, the fact that the angulus region allows the most reliable determination of ROIs and is the least affected by external factors such as artifacts may have contributed to the presence of a statistically significant difference only in this region.

Our results are partially align with those of Sobolewska *et al.* [23], who reported higher FD values on the infraoccluded sides in children aged 8–13 years. However, their study used the Fourier method and averaged FD values rather than analyzing multiple distinct ROIs [23]. The aim of the study by Kaya and Avcı was to evaluate the mandibular trabecular bone structure in the apical region of primary molars with unilateral and bilateral infraocclusion using the FD analysis method. A total of 43 primary molars with infraocclusion from individuals aged 12 to 30 years were included. The results showed no statistically significant difference between unilateral and bilateral involvement. Unlike the present study, FD values in the apical regions of unilaterally affected teeth were found to be lower than those of their contralateral counterparts, although this difference was not statistically significant. Additionally, no significant relationship was found between the degree of root resorption and FD values in teeth with bilateral infraocclusion on the right and left sides [22]. Similar to the aforementioned research, our analysis also employed the box-counting method based on the protocol by White and Rudolph [28]. However, that study evaluated only a single ROI located in the apical region, whereas our investigation included multiple mandibular areas.

Among other studies in the field of paediatric dentistry, Günacar *et al.* [32] evaluated the relationship between dental caries and jawbone trabeculation in children aged 8–13 years, considering that dental caries may affect masticatory forces during growth and development. Their results indicated no significant relationship between dental caries and jawbone trabeculation [32]. In another study, Kolçakoğlu *et al.* [33] Analyzed mandibular trabecular bone density using FD analysis on panoramic radiographs of 37 paediatric patients diagnosed with sleep bruxism. Their findings revealed significantly higher FD values in the mandibular angle and condylar regions among bruxism patients compared to the controls, suggesting a potential impact of sleep bruxism on trabecular bone density [33].

Southard *et al.* [34] suggested that a decreased FD values might be associated with a decrease in bone density. Similarly, Sobolewska *et al.* [23], interpreted higher FD values in infraoccluded regions as indicative of increased bone density. In this context, clinically observed ankylosis and reduced physiological mobility of infraoccluded teeth further support the hypothesis of denser bone structure surrounding these teeth.

Limited research exists concerning the effects of hypodontia on trabecular bone structure [35, 36]. The present study found significantly higher FD values in the condylar region of individuals possessing permanent tooth germs compared

to those without. In line with our findings, Temur *et al.* [35] evaluated FD values on panoramic radiographs from 69 pediatric patients with congenital absence of second premolars, reporting significantly lower FD values in the ramus region of the hypodontia group compared to controls. This finding is in line with the general trend observed in the present study; however, in our case the significant difference was found in the condylar region. Conversely, Créton *et al.* [36] identified no significant differences in mandibular trabecular bone FD values between adults with and without hypodontia.

Severe infraocclusion treatment strategies include composite or stainless steel crowns to raise the occlusal plane, prosthetic restorations after extraction, space maintainers, and orthodontic interventions. Treatment planning varies according to tooth prognosis, patient age, and the presence of tooth germs. Orthodontic treatment and dental implants are often considered to preserve the existing bone structure after extraction, but these procedures are generally delayed until growth and development are complete, typically around the age of 16–20 years [37]. In orthodontic treatment, it is emphasised that tooth movement may be accelerated in areas of reduced bone density, and increased anchorage may be required in areas of low bone density [38]. Therefore, in clinical practice, a detailed assessment of the bone structure in individuals with infraocclusion is essential. However, further studies with larger sample sizes are needed to clarify the association between increased FD values and bone density in infraoccluded regions.

FD analysis is a non-invasive, cost-effective, and practical method for assessing trabecular bone patterns using conventional radiographs [30]. Compared to periapical radiographs, panoramic images have lower resolution, which may limit the detection of fine trabecular structures. While periapical radiographs offer higher image clarity in localized regions, their limited anatomical coverage and difficulties in obtaining reliable images from pediatric patients reduce their practicality [39]. In contrast, cone-beam computed tomography (CBCT) allows detailed 3D evaluation of bone microarchitecture but its disadvantages include high cost, limited accessibility, and greater radiation exposure [40]. Thus, FD analysis performed on two-dimensional panoramic radiographs remains a clinically valuable alternative due to its lower radiation dose, widespread availability, ease of use, and suitability for screening purposes in children. Moreover, FD analysis facilitates objective, quantitative evaluation of bone complexity that surpasses traditional subjective visual assessments, enhancing diagnostic consistency and enabling earlier detection of subtle structural bone alterations. However, routine clinical implementation of FD analysis requires adequate familiarity and experience with digital image processing software, highlighting a need for targeted clinician training.

This research has several limitations. Firstly, fractal analysis was performed using digital panoramic radiographs, which have a lower resolution than periapical radiographs. Previous research by Bollen *et al.* [41] has shown that FD values derived from panoramic images tend to be lower, presumably because of the reduced ability to visualise fine trabecular details. Furthermore, it was challenging to define consistent ROIs in the mandibular molar area, particularly due to the difficulty of locating anatomical landmarks such as the mental foramen in

mixed dentition. Although reliable ROIs could be identified in the condylar and angulus regions, this limitation may have affected the accuracy of FD measurements in the molar region. The use of periapical radiographs may allow for a more precise evaluation of the trabecular bone structure in infraoccluded primary molars in subsequent studies.

5. Conclusions

Significant differences in FD values in specific mandibular regions suggest structural trabecular bone changes related to infraocclusion, enhancing the understanding of its etiology and clinical implications. Future research with larger samples and periapical radiographs is recommended to validate these findings.

ABBREVIATIONS

CBCT, Cone-beam computed tomography; FD, Fractal dimension; ICC, Intraclass correlation coefficient; ROI, Regions of interest; PACS, Picture Archiving and Communication System.

AVAILABILITY OF DATA AND MATERIALS

The data that support the findings of this study are available from the corresponding author EEÇ, upon reasonable request.

AUTHOR CONTRIBUTIONS

EEÇ, YÇ and NA—designed the research study; performed the research. EEÇ—analyzed the data; wrote the manuscript. YÇ and NA—revised and edited the manuscript. All authors read and approved the final manuscript.

ETHICS APPROVAL AND CONSENT TO PARTICIPATE

The study was approved by Gazi University Ethics Committee on 18 February 2025 with the decision number E-77082166-604.01-1178259. Informed consent was obtained from the parents or legal guardians of all participants prior to their inclusion in the study.

ACKNOWLEDGMENT

Not applicable.

FUNDING

This research received no external funding.

CONFLICT OF INTEREST

The authors declare no conflict of interest.

REFERENCES

- [1] Odeh R, Mihailidis S, Townsend G, Lähdesmäki R, Hughes T, Brook A. Prevalence of infraocclusion of primary molars determined using a new 2D image analysis methodology. *Australian Dental Journal*. 2016; 61: 183–189.
- [2] Hua L, Thomas M, Bhatia S, Bowkett A, Merrett S. To extract or not to extract? Management of infraoccluded second primary molars without successors. *British Dental Journal*. 2019; 227: 93–98.
- [3] Andersson L, Blomlöf L, Lindskog S, Feiglin B, Hammarström L. Tooth ankylosis: clinical, radiographic and histological assessments. *International Journal of Oral Surgery*. 1984; 13: 423–431.
- [4] Kurol J, Magnusson BC. Infraocclusion of primary molars: a histologic study. *European Journal of Oral Sciences*. 1984; 92: 564–576.
- [5] Bjerklin K, Al-Najjar M, Kårestedt H, Andrén A. Agenesis of mandibular second premolars with retained primary molars. A longitudinal radiographic study of 99 subjects from 12 years of age to adulthood. *The European Journal of Orthodontics*. 2008; 30: 254–261.
- [6] Lai P, Seow W. A controlled study of the association of various dental anomalies with hypodontia of permanent teeth. *Pediatric Dentistry*. 1989; 11: 291–296.
- [7] Bezgin T, Özgül BM, Demirel A, Sarı Ş. Dental anomalies associated with mandibular second premolar agenesis. *Türkiye Klinikleri Pediatric Dentistry-Special Topics*. 2015; 1: 6–12. (In Turkish)
- [8] Harokopakis-Hajishengallis E. Physiologic root resorption in primary teeth: molecular and histological events. *Journal of Oral Science*. 2007; 49: 1–12.
- [9] Demirel A, Sarı Ş. Are increased masticatory forces risk for primary 2nd molars without successors? A 3D FEA study. *Journal of Clinical Pediatric Dentistry*. 2019; 43: 64–68.
- [10] Franciotti R, Moharrami M, Quaranta A, Bizzoca ME, Piattelli A, Aprile G, *et al.* Use of fractal analysis in dental images for osteoporosis detection: a systematic review and meta-analysis. *Osteoporosis International*. 2021; 32: 1041–1052.
- [11] Sánchez I, Uzcátegui G. Fractals in dentistry. *Journal of Dentistry*. 2011; 39: 273–292.
- [12] Updike SX, Nowzari H. Fractal analysis of dental radiographs to detect periodontitis-induced trabecular changes. *Journal of Periodontal Research*. 2008; 43: 658–664.
- [13] Jurczynsyn K, Kubasiewicz-Ross P, Nawrot-Hadzik I, Gedrange T, Dominiak M, Hadzik J. Fractal dimension analysis a supplementary mathematical method for bone defect regeneration measurement. *Annals of Anatomy*. 2018; 219: 83–88.
- [14] Eser S, Sarıbaş E. Anatomical assessment of the trabecular structure of the alveolar bone in periodontal disease by fractal analysis method. *Folia Morphologica*. 2024; 83: 157–167.
- [15] Mishra S, Kumar M, Mishra L, Panda S, Panda S, Lewkowicz N, *et al.* Estimation of cancellous changes using fractal analysis in patients with periodontitis. *Biomedicine*. 2023; 11: 2547.
- [16] Kumar SS, Nagi R, Chacko R, Khan J. The effectiveness of fractal analysis in diagnosing temporomandibular joint disorders: a systematic review of clinical studies. *Oral Radiology*. 2024; 41: 153–168.
- [17] Iezzi G, Aprile G, Tripodi D, Scarano A, Piattelli A, Perrotti V. Implant surface topographies analyzed using fractal dimension. *Implant Dentistry*. 2011; 20: 131–138.
- [18] Huang C, Chen J, Chang Y, Jeng J, Chen C. A fractal dimensional approach to successful evaluation of apical healing. *International Endodontic Journal*. 2013; 46: 523–529.
- [19] Umemori S, Tonami K, Nitta H, Matakai S, Araki K. The possibility of digital imaging in the diagnosis of occlusal caries. *International Journal of Dentistry*. 2010; 2010: 860515.
- [20] Mincione G, Di Nicola M, Di Marcantonio MC, Muraro R, Piattelli A, Rubini C, *et al.* Nuclear fractal dimension in oral squamous cell carcinoma: a novel method for the evaluation of grading, staging, and survival. *Journal of Oral Pathology & Medicine*. 2015; 44: 680–684.
- [21] Kato CN, Barra SG, Tavares NP, Amaral TM, Brasileiro CB, Mesquita RA, *et al.* Use of fractal analysis in dental images: a systematic review. *Dentomaxillofacial Radiology*. 2020; 49: 20180457.
- [22] Kaya S, Avcı B. Evaluation of the fractal dimension in the apical region of primary teeth with unilateral and bilateral infraocclusion. *Cumhuriyet Dental Journal*. 2024; 27: 127–135.

- [23] Sobolewska-Siemieniuk M, Grabowska SZ, Oczeretko E, Kitlas A, Borowska M. Fractal analysis of mandibular radiographic images in the region of reincluded teeth. *Czasopismo Stomatologiczne*. 2007; 60: 593–600. (In Polish)
- [24] Faul F, Erdfelder E, Buchner A, Lang AG. Statistical power analyses using G*Power 3.1: tests for correlation and regression analyses. *Behavior Research Methods*. 2009; 41: 1149–1160.
- [25] Gulec M, Tassoker M, Ozcan S, Orhan K. Evaluation of the mandibular trabecular bone in patients with bruxism using fractal analysis. *Oral Radiology*. 2021; 37: 36–45.
- [26] Brearley LJ, McKibben DH III. Ankylosis of primary molar teeth. I. Prevalence and characteristics. *ASDC Journal of Dentistry for Children*. 1973; 40: 54–63.
- [27] Patano A, Inchingolo AM, Laudadio C, Azzollini D, Marinelli G, Ceci S, *et al*. Therapeutic strategies of primary molar infraocclusion: a systematic review. *Children*. 2023; 10: 582.
- [28] White SC, Rudolph DJ. Alterations of the trabecular pattern of the jaws in patients with osteoporosis. *Oral Surgery, Oral Medicine, Oral Pathology, Oral Radiology, and Endodontology*. 1999; 88: 628–635.
- [29] Suer BT, Yaman Z, Buyuksarac B. Correlation of fractal dimension values with implant insertion torque and resonance frequency values at implant recipient sites. *International Journal of Oral & Maxillofacial Implants*. 2016; 31: 55–62.
- [30] Sevimay MA, Gürsu M, Çeçe MA, Çankal DA, Akarslan Z, Çetiner S. Fractal dimension analysis of mandibular trabecular bone in patients receiving antiresorptive therapy for osteoporosis and oncologic conditions. *Diagnostics*. 2025; 15: 748.
- [31] Çitir M, Karslioglu H, Uzun C. Evaluation of mandibular trabecular and cortical bone by fractal analysis and radiomorphometric indices in bruxist and non-bruxist patients. *BMC Oral Health*. 2023; 23: 522.
- [32] Gunacar DN, Erbek SM, Aydınoglu S, Kose TE. Evaluation of the relationship between tooth decay and trabecular bone structure in pediatric patients using fractal analysis: a retrospective study. *European Oral Research*. 2022; 56: 67–73.
- [33] Kolcakoglu K, Amuk M, Sirin Saribal G. Evaluation of mandibular trabecular bone by fractal analysis on panoramic radiograph in paediatric patients with sleep bruxism. *International Journal of Paediatric Dentistry*. 2022; 32: 776–784.
- [34] Southard TE, Southard KA, Jakobsen JR, Hillis SL, Najim CA. Fractal dimension in radiographic analysis of alveolar process bone. *Oral Surgery, Oral Medicine, Oral Pathology, Oral Radiology, and Endodontology*. 1996; 82: 569–576.
- [35] Temur KT, Magat G, Coskunarslan A, Önsüren AS, Özcan S. Evaluation of mandibular trabecular bone by fractal analysis in pediatric patients with hypodontia. *BMC Oral Health*. 2024; 24: 1005.
- [36] Créton M, Geraets W, Verhoeven JW, van der Stelt PF, Verhey H, Cune M. Radiographic features of mandibular trabecular bone structure in hypodontia. *Clinical Implant Dentistry and Related Research*. 2012; 14: 241–249.
- [37] Robinson S, Chan MW. New teeth from old: treatment options for retained primary teeth. *British Dental Journal*. 2009; 207: 315–320.
- [38] Chugh T, Jain AK, Jaiswal RK, Mehrotra P, Mehrotra R. Bone density and its importance in orthodontics. *Journal of Oral Biology and Craniofacial Research*. 2013; 3: 92–97.
- [39] Aniyo R, Kaur G. Different techniques of dental radiography for paediatric patients: a review. *Journal of Advanced Medical and Dental Sciences Research*. 2019; 7: 75–79.
- [40] Baydar O, Onem E, Mert A, Baksi BG. Evaluation of trabecular bone microstructure and cortical morphology using cone-beam and micro-CT images: impact of tube voltage setting. *BMC Oral Health*. 2025; 25: 664.
- [41] Bollen A, Taguchi A, Hujoel P, Hollender L. Fractal dimension on dental radiographs. *Dentomaxillofacial Radiology*. 2001; 30: 270–275.

How to cite this article: Ecem Elif Çeçe, Yasemin Çamlıbel, Neşe Akal. Fractal dimension analysis of mandibular trabecular bone in severely infraoccluded primary molars: a retrospective case-control study. *Journal of Clinical Pediatric Dentistry*. 2026; 50(1): 196-205. doi: 10.22514/jocpd.2026.019.