

ORIGINAL RESEARCH

Clinical evaluation of permanent molars diagnosed by irreversible pulpitis with apical periodontitis treated by MTA pulpotomy

Han Qin^{1,*}, Jun Cai²

¹Department of Stomatology, The Lianyungang Affiliated Hospital of Xuzhou Medical University, 222002 Lianyungang, Jiangsu, China

²Department of Anesthesia, The Maternal and Child Health Hospital of Lianyungang City, 222006 Lianyungang, Jiangsu, China

*Correspondence
qinhan2005@163.com
(Han Qin)

Abstract

Background: This study examined the clinical effects of mineral trioxide aggregate (MTA) pulpotomy for permanent molars with caries-derived pulpitis with symptomatic apical periodontitis. **Methods:** Based on symptomatic apical periodontitis or not, 52 permanent molars with pulp exposure due to caries were divided into 29 in the non-symptomatic apical periodontitis group and 23 in the symptomatic apical periodontitis group. **Results:** Regardless of the root development degree, both groups were treated with different depths of pulpotomy according to pulp status and bleeding. Clinical and radiological examinations were scheduled for follow-up after 1, 3, 6 and 12 months to undergo clinical and radiological examination. A success rate of 96.6% was achieved in the non-symptomatic apical periodontitis group; 91.3% was achieved in the symptomatic apical periodontitis group. There was no significant difference between both groups ($\chi^2 = 0.65$, $p = 0.42$). **Conclusions:** MTA pulpotomy is an effective treatment for caries-derived pulpitis in permanent molars with symptomatic apical periodontitis, offering a new approach for clinical treatment.

Keywords

Cariogenic pulp exposure; Permanent molar; Pulpotomy; Pulpitis with symptomatic apical periodontitis

1. Introduction

Clinical treatment options are more complicated when permanent molars have caries-derived pulp exposure with symptomatic apical periodontitis [1, 2]. For pediatric stomatology patients under 14 years, permanent molars development may range, from formation only 1/3 of the tooth roots to completing apical foramen development. In previous studies, pulpotomies have been found to be primarily performed on young permanent teeth with undeveloped apical foramen and crown pulp lesions [1]. As research and materials continue to advance, more scholars are adopting pulpotomy for mature permanent teeth confined to the crown pulp [3–5]. However, few studies have examined whether pulpotomy can be applied when pulp infection extends beyond the apical foramen with obvious symptomatic apical periodontitis. Therefore, we performed pulpotomy and follow-up observation on caries-derived pulpitis with symptomatic apical periodontitis, compared with the group without symptomatic apical periodontitis. We speculate that both groups can achieve better therapeutic effects.

2. Materials and method

2.1 Experimental subjects

A total of 52 caries-derived pulp exposed permanent molars were selected from 42 children treated in the pediatric stomatology department from January 2019 to December 2021. There were 36 first permanent molars and 16 second permanent molars among all participants. According to whether they were had symptomatic apical periodontitis or not, 29 were assigned to the non-symptomatic apical periodontitis group and 23 to the symptomatic apical periodontitis group. 19 males and 23 females ranged in age from 7 to 14 years. The size of exposed myeloid foramen varied from needle-like punctures to partial exposure of root pulp. Tooth pain duration varied from initial pain to recurring pain for more than 6 months. As this study did not involve the collection of clinical specimens, it only involved X-ray observations required for routine follow-up. In addition, the entire clinical process can only be seen as patients choosing different treatment plans, so there is no need for clinical trial registration.

All the affected teeth met the following criteria: history of spontaneous pain; pulp exposure found in the examination; positive pain in the exposed pulp; teeth with symptomatic apical periodontitis suffered from obvious percussion pain. The exclusion criteria were as follows: combined periodontitis and loose teeth; accompanied by tooth root fracture; and the

child was unable to cooperate. All participants were provided with information sheets about the study's objectives the relevant treatment process, and the need for cooperation. Each participant's legal guardian signed the consent form.

2.2 Pulpotomy and follow up

Both groups were isolated with a rubber barrier under local anesthesia, and pulpotoomies at different depths were performed using a high-speed ball drill according to pulp status and bleeding (the bleeding could be controlled within 5 minutes). Pulp was covered by MTA (Tulsa Dental Products, Tulsa, OK, USA), the pulp cavity was kept moist by a normal saline cotton ball, and zinc oxide (Shanghai Medical Equipment Co., LTD. Dental materials factory, Shanghai, China) was temporarily sealed. After 24 hours, the temporary filling was removed, and the dental crown section was repaired with light curing resin (3M Company, Paul, MNUS, USA).

A series of the clinical symptoms and positive signs were monitored at 1, 3, 6 and 12 months after treatment. The criteria for treating a patient successfully are no subjective discomfort, no abnormalities were found during the clinical examination. According to the changes in root length, pulp cavity and root canal wall thickness, X-ray film (Blue X Imaging SRL, VIA IDIOMI 1/8-33-20090 ASSAGO (MI), Italy) was used to assess the vitality of the root pulp and the development trend of the root. When the periapical tissue shadow was identified, the root development stopped or the root internal and external absorption occurred, apexification or root canal therapy was performed according to the degree of root development.

2.3 Data statistics and analysis

Data analysis was performed using SPSS 21.0 software (SPSS Incorporated, Chicago, IL, USA). Chi-square test was used to evaluate the effect of different treatment methods. Statistical data results were expressed as mean \pm standard deviation, and $p < 0.05$ was considered statistically significant.

3. Results

3.1 Evaluation of apical lesion healing

Based on the above treatment success criteria, 28 of the 29 affected teeth in the non-symptomatic apical periodontitis group, and 21 of the 23 affected teeth in the symptomatic apical periodontitis group were successful, as shown in Table 1. In a Chi-square test, no significant differences were found between both groups ($\chi^2 = 0.65, p = 0.42$).

3.2 Typical case

3.2.1 Typical cases in non-symptomatic apical periodontitis group

3.2.1.1 A 13-year-old male

He presented with spontaneous pain in the right lower posterior tooth for 2 weeks. Teeth 47 had deep caries with exposed pulp, probing pain (+), percussion pain (-), no loosening, root development of about 1/3, no periapical low-density imaging was observed. We performed a full pulpotomy under local anesthesia, followed by MTA capping. After 12 months of

TABLE 1. Assessment of apical lesion healing at 12 months follow-up.

| | Success | Fail | Sum | Success rate |
|--|---------|------|-----|--------------|
| Non-symptomatic apical periodontitis group | 28 | 1 | 29 | 96.6% |
| Symptomatic apical periodontitis group | 21 | 2 | 23 | 91.3% |
| Sum | 49 | 3 | 52 | 94.2% |

Note. Chi-square test showed no statistically significant difference between the two groups, $p > 0.05$.

follow-up, apical foramen had essentially formed (Fig. 1).

3.2.1.2 A 10-year-old male

He was diagnosed with spontaneous pain in the right lower posterior tooth for 3 days. Teeth 46 fillings were partially exfoliated and exposed pulp, probing pain (+), percussion pain (-), no loosening, uncompleted apical foramen development, and no periapical low-density imaging was observed. We performed a full pulpotomy under local anesthesia, followed by MTA capping. After 12 months of follow-up, apical foramen had essentially formed (Fig. 2).

3.2.1.3 A 13-year-old female

She presented with spontaneous pain in the right lower posterior tooth for 1 week. Teeth 46 had deep caries with exposed pulp, probing pain (+), percussion pain (-), no loosening, completed apical foramen development, and no periapical low-density imaging was observed. We performed a full pulpotomy under local anesthesia, followed by MTA capping. After 12 months of follow-up, no subjective discomfort, and abnormalities were found during clinical examination (Fig. 3).

3.2.2 Typical cases in symptomatic apical periodontitis group

3.2.2.1 A 8-year-old female

She presented with left lower posterior tooth spontaneous pain for 2 months. Teeth 36 had deep caries with exposed pulp, probing pain (+), percussion pain (+), no loosening, uncompleted apical foramen development, periapical low-density imaging was observed. We performed a full pulpotomy under local anesthesia, followed by MTA capping. After 12 months of follow-up, apical foramen had essentially formed and no periapical low-density imaging was observed (Fig. 4).

3.2.2.2 A 12-year-old male

He was diagnosed with spontaneous pain in the left lower posterior tooth for 1 month, and received treatment for dental pain in another hospital 3 months ago. Teeth 36 temporary fillings were partially shed, probing pain (+), percussion pain

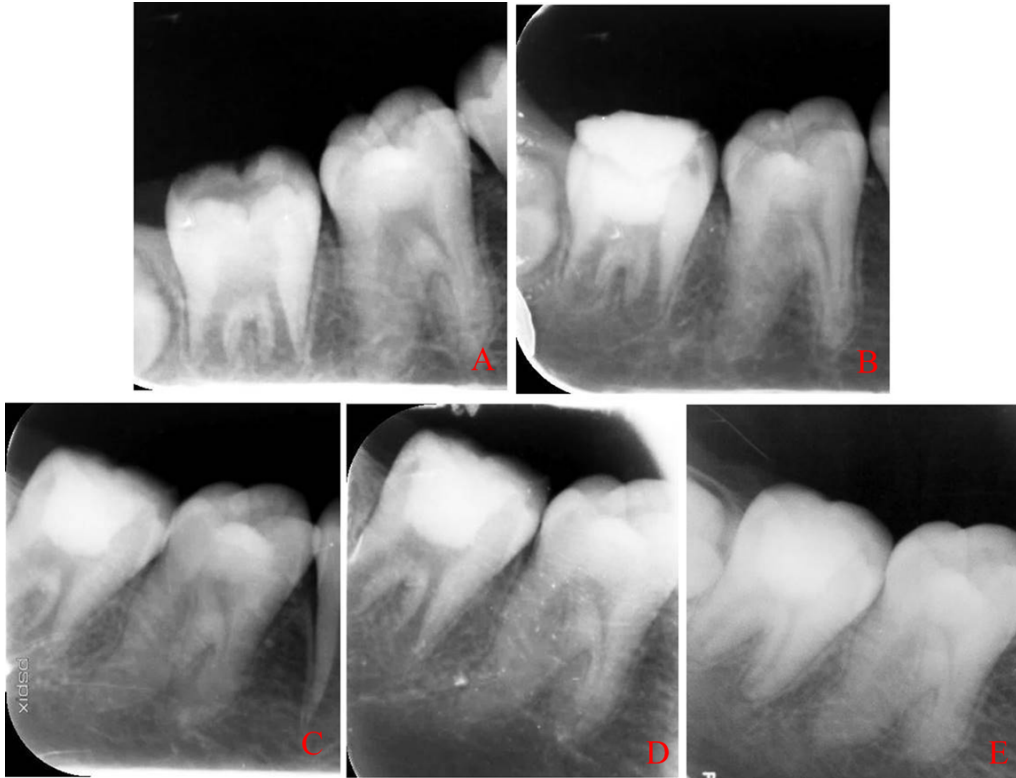


FIGURE 1. Examples of X-rays taken in non-symptomatic apical periodontitis group at the beginning of treatment and during follow-up. (A) initial, (B) immediately after surgery, (C) 3 months follow-up, (D) 6 months follow-up, (E) 12 months follow-up.

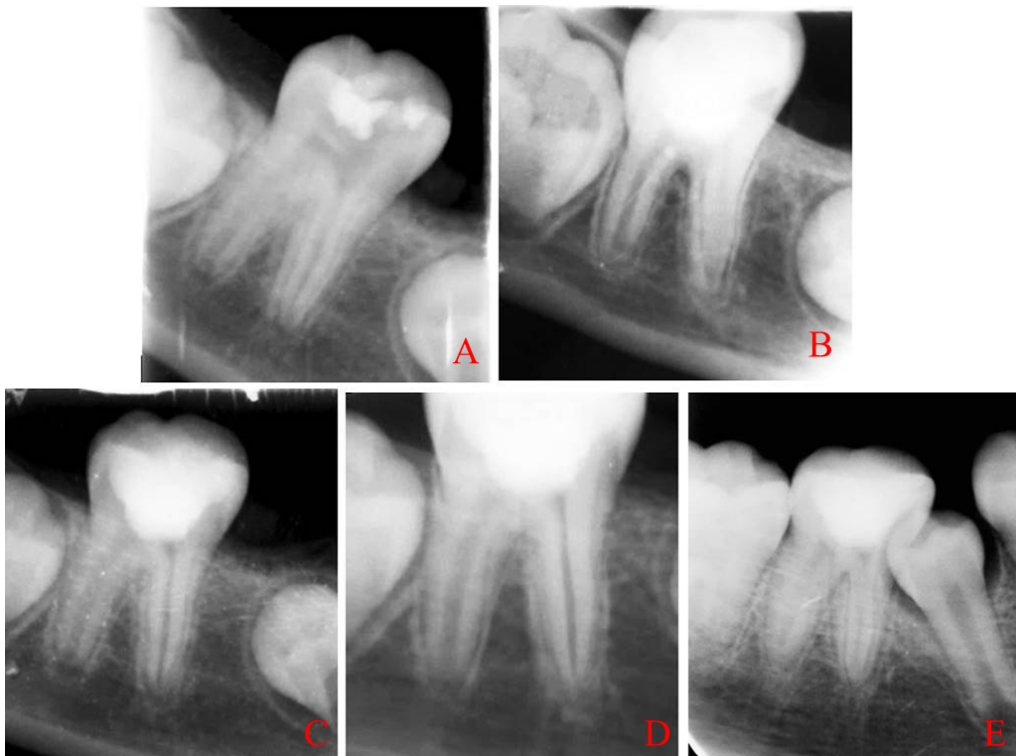

FIGURE 2. Examples of X-rays taken in non-symptomatic apical periodontitis group at the beginning of treatment and during follow-up. (A) initial, (B) immediately after surgery, (C) 3 months follow-up, (D) 6 months follow-up, (E) 12 months follow-up.

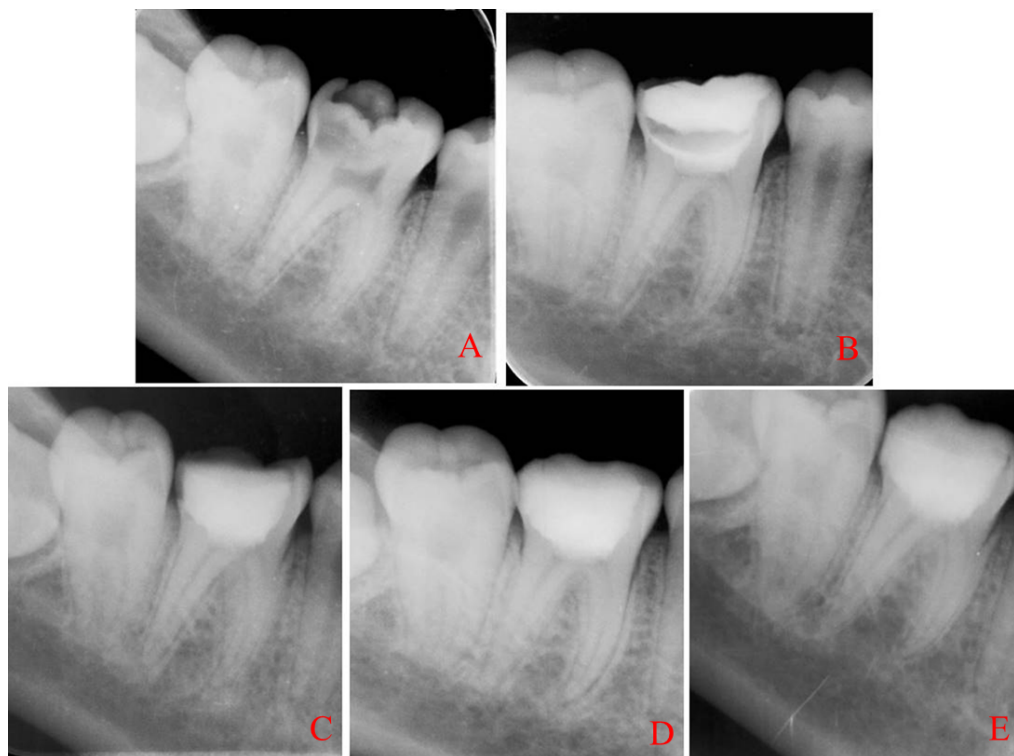

FIGURE 3. Examples of X-rays taken in non-symptomatic apical periodontitis group at the beginning of treatment and during follow-up. (A) initial, (B) immediately after surgery, (C) 3 months follow-up, (D) 6 months follow-up, (E) 12 months follow-up.

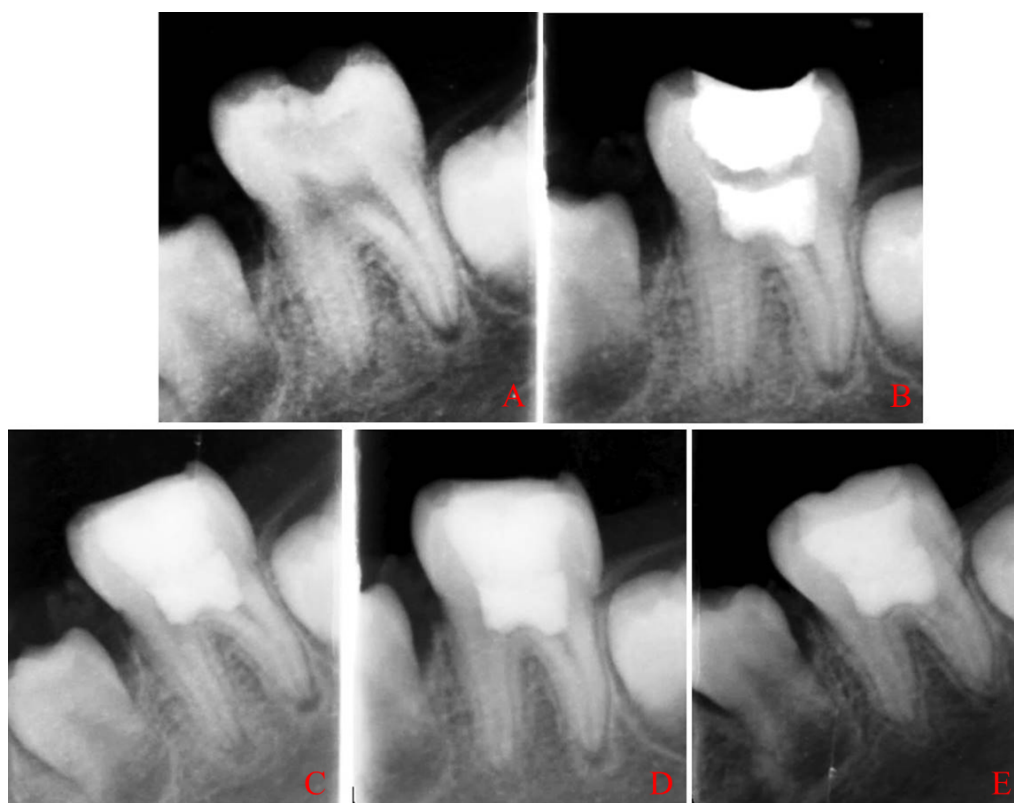

FIGURE 4. Examples of X-rays taken in symptomatic apical periodontitis group at the beginning of treatment and during follow-up. (A) initial, (B) immediately after surgery, (C) 3 months follow-up, (D) 6 months follow-up, (E) 12 months follow-up.

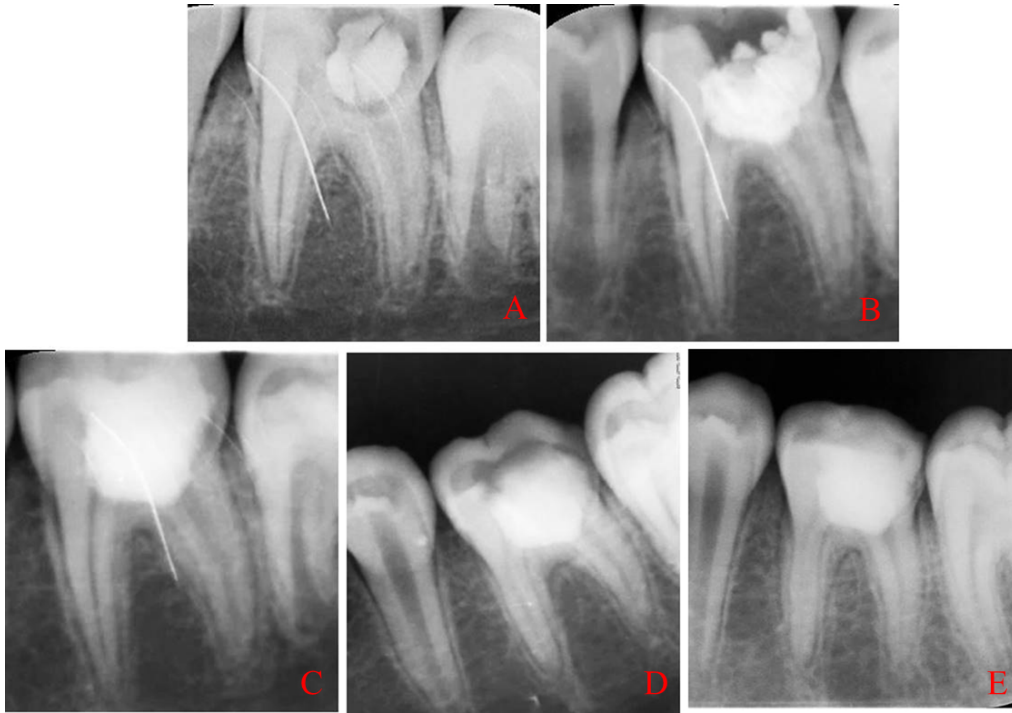


FIGURE 5. Examples of X-rays taken in symptomatic apical periodontitis group at the beginning of treatment and during follow-up. (A) initial, (B) immediately after surgery, (C) 3 months follow-up, (D) 6 months follow-up, (E) 12 months follow-up.

(+), no loosening, completed apical foramen development, periapical low-density imaging was observed. We performed a full pulpotomy under local anesthesia, followed by MTA capping. After 12 months of follow-up, no periapical low-density imaging was observed (Fig. 5).

3.2.2.3 A 13-year-old female

She presented with spontaneous pain in the right lower posterior tooth for 3 weeks. Teeth 46 had deep caries with exposed pulp, probing pain (+), percussion pain (+), no loosening, completed apical foramen development, periapical low-density imaging was observed. We performed a full pulpotomy under local anesthesia, followed by MTA capping. After 12 months of follow-up, no periapical low-density imaging was observed (Fig. 6).

4. Discussion

Living pulp preservation therapy preserves healthy pulp tissue, which promotes restorative dentin formation and maintains teeth's normal physiological functions. Considering its minimally invasive nature, it is significant development trend in contemporary endodontic therapy [6, 7]. As long as the infection can be completely removed, healthy pulp tissue can be preserved successfully with pulpotomy for caries-derived pulp exposures [8, 9]. However, it is unclear whether living pulp amputation can be used with symptomatic apical periodontitis when pulp infection has permeated part of the root pulp. Past beliefs held that pulp tissue could not be retained during infection invaded the root pulp and symptomatic apical periodontitis. It is necessary at this point to perform root canal treatment on mature permanent teeth. Young permanent

teeth with incomplete apical foramina development require the preservation of the apical papilla to induce apical development, restore pulp blood supply or regenerate pulp. Physicians' skills and equipment performances are highly demanding for each of these tasks [10]. Recent advances in molecular biology, histopathology, materials science and clinical research supported pulpotomy as a viable concept [11, 12].

We selected 52 cariogenic pulp-exposed permanent molars and divided them into 29 in the non-symptomatic apical periodontitis group and 23 in the symptomatic apical periodontitis group. During pulpotomy, we did not consider whether there was symptomatic apical periodontitis, and chose different living pulp amputation depths based on the control degree of bleeding. A success rate of 96.6% (1 failed) was achieved in the non-symptomatic apical periodontitis group. 91.3% (2 failed) was achieved in the symptomatic apical periodontitis group. The 3 failed teeth were all found to have pulpitis, and 1 had symptomatic apical periodontitis, but they were all associated with more intraoperative bleeding. It is suggested that the key to the pulpotomy success lies in the removal of infected tissue, and an important criterion in the treatment is the ability to effectively control bleeding, while whether there is symptomatic apical periodontitis does not play a decisive role in the success rate of treatment. Pulpotomy has higher pain control efficiency than root canal therapy, while being simpler and less invasive [10]. This study suggests that despite pulpitis accompanied by symptomatic apical periodontitis, pulpotomy can provide better therapeutic outcomes when inflammation is effectively controlled.

There is a questionable correlation between pulp tissue healing ability and root development degree [13, 14]. Conventional

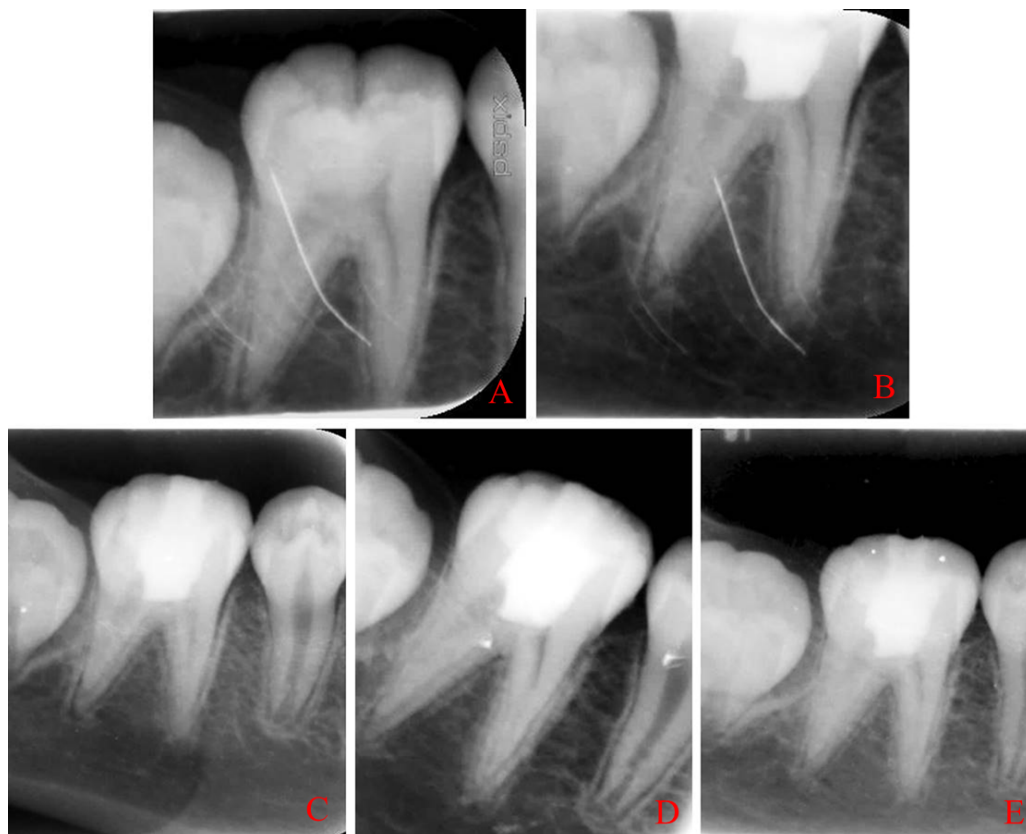


FIGURE 6. Examples of X-rays taken in symptomatic apical periodontitis group at the beginning of treatment and during follow-up. (A) initial, (B) immediately after surgery, (C) 3 months follow-up, (D) 6 months follow-up, (E) 12 months follow-up.

wisdom holds that young patients have better healing abilities for pulp tissue, which increases pulp survival rates. A pulpotomy is not recommended for mature permanent teeth, since the apical foramen is closed during root development. The pulp tissue only relies on the narrow apical foramina to obtain blood supply. Pulpotomy, however, has proven to be more effective in treating affected tooth with fully developed apical foramina [15–17]. In this study, we selected first or second molar teeth from pediatric stomatology patients. Root development degree was not clearly defined, ranging from 1/3 or the root length to the complete apical foramen development. An aseptic pulpotomy was performed on all children with a rubber barrier. It was found that all patients achieved significant therapeutic effects despite varying degrees of apical foramen development. 3 cases of treatment failure occurred in both groups. 2 involved incomplete apical foramina development and 1 involved complete apical foramina development. Apical foramen had no statistically significant effect on pulpotomy success rates, indicating that the apical foramen's development was not the main factor in selecting pulpotomy [18]. In line with previous research, there is no direct relationship between apical foramen development degrees and pulpotomy success rates. However, due to the small sample size and brief observation period of this study, further investigation of apical foramen status on pulpotomy prognosis is still required.

Preservation of pulp vitality is the basic principle of the clinical treatment of endodontic diseases. Its success depends on many factors, including dental caries depth, pulp infection

scope, hemostasis control during the operation and materials biological properties [19, 20]. The pulp agent must be covered after pulpotomy to prevent the invasion of pathogenic microorganisms and the external adverse stimuli. At the same time, through the pulpectomy material, stem cells in the pulp tissue are induced to differentiate into odontoblast cells, thus promoting the formation of a hard tissue barrier. Pulp tissue can be protected from micro-organisms invasion, thereby delaying root canal treatment and improving the long-term survival rate of the affected tooth [21, 22]. MTA plays crucial role in living pulp resection because of its good histocompatibility, tight leak-proof performance, and strong ability to induce restorative dentin formation. As MTA caps the pulp, it is more tightly bound to the wall of the pulp cavity, resulting a tighter seal, facilitating the formation of restorative dentin [23–25].

Both groups used MTA after pulpotomy to cap the pulp. The cure rate of two components was above 90%, indicating that MTA can preserve pulps well. We analyzed failure cases and found that incomplete MTA curing occurred at 24-hour dressing change. The reasons were as follows: (1) Despite strict bleeding control during pulpotomy, small amounts of blood leakage cannot be excluded later. (2) MTA needs to be fully cured in humid environment, however if the inflammation is not well controlled, bleeding may significantly affect its performance, resulting in incomplete curing. (3) Lack of timely replenishment of material above the incomplete solidified MTA led to microleakage that caused poor calcification bridge formation. Thus, inflammation and excessive bleeding

occur during pulpotomy, resulting in not only an easy shift of the pulp capping agent, but also a blockage of pulp capping agent and the pulp segment, affecting the formation of restorative dentin and calcification rate. Materially, this indicates that good control of inflammation is crucial for pulpotomy success. As a result of the limitations of conditions, the existing histological study period is short, and the long-term hard tissue changes cannot be observed [26, 27].

5. Conclusions

This study indicates that pulpotomy is more effective if inflammation is effectively controlled, regardless of whether symptomatic apical periodontitis exists or the apical foramen is developed. Clinical practice is still plagued by numerous problems, for example, the lack of objective criteria and clinical norms for selecting indications and treatment methods, the need for new methods to accurately assess pulp status and pulpitis degree, as well as long-term histological observations of pulp tissue after treatment. New diagnostic and treatment techniques are expected to lead to more accurate and less invasive endodontic treatment with research advancement.

AVAILABILITY OF DATA AND MATERIALS

The data presented in this study are available on reasonable request from the corresponding author.

AUTHOR CONTRIBUTIONS

HQ, JC—designed the research study; analyzed the data. HQ—performed the research; wrote the manuscript. Both authors read and approved the final manuscript.

ETHICS APPROVAL AND CONSENT TO PARTICIPATE

All procedures of this study were carried out in accordance with relevant guidelines and approved by Lianyungang Affiliated Hospital of Xuzhou Medical University (Grant number: LW-20231109001). And the informed consent was obtained from the patient and his parents.

ACKNOWLEDGMENT

The authors are grateful to the patient and his family members for their kind cooperation and participation.

FUNDING

This research was funded by the 521 Scientific Research Project of Lianyungang City (Grant number: LYG 06521202362).

CONFLICT OF INTEREST

The authors declare no conflict of interest.

REFERENCES

- [1] Shetty P, Shetty S, Rai P, Kumar BK, Bhat R. Role of oral microbiota in irreversible pulpitis—current strategies and future perspectives. *Acta Microbiol Immunol Hung*. 2023; 70: 177–186.
- [2] Hellyer P. Pulpotomy and pulpitis. *British Dental Journal*. 2022; 232: 459.
- [3] Ramanandvignesh P, Gyanendra K, Jatinder Kaur Goswami Mridula D. Clinical and radiographic evaluation of pulpotomy using MTA, Biodentine and Er,Cr:YSGG laser in primary teeth—a clinical study. *Laser Therapy*. 2020; 29: 29–34.
- [4] Vafaei A, Nikookhesal M, Erfanparast L, Løvschall H, Ranjkesh B. Vital pulp therapy following pulpotomy in immature first permanent molars with deep caries using novel fast-setting calcium silicate cement: a retrospective clinical study. *Journal of Dentistry*. 2022; 116: 103890.
- [5] Tomson PL, Vilela Bastos J, Jacimovic J, Jakovljevic A, Pulikkotil SJ, Nagendrababu V. Effectiveness of pulpotomy compared with root canal treatment in managing non-traumatic pulpitis associated with spontaneous pain: a systematic review and meta-analysis. *International Endodontic Journal*. 2023; 56: 355–369.
- [6] Ramani A, Sangwan P, Tewari S, Duhan J, Mittal S, Kumar V. Comparative evaluation of complete and partial pulpotomy in mature permanent teeth with symptomatic irreversible pulpitis: a randomized clinical trial. *International Endodontic Journal*. 2022; 55: 430–440.
- [7] Yong D, Cathro P. Conservative pulp therapy in the management of reversible and irreversible pulpitis. *Australian Dental Journal*. 2021; 66: S4–S14.
- [8] Jassal A, Nawal RR, Yadav S, Talwar S, Yadav S, Duncan HF. Outcome of partial and full pulpotomy in cariously exposed mature molars with symptoms indicative of irreversible pulpitis: a randomized controlled trial. *International Endodontic Journal*. 2023; 56: 331–344.
- [9] Cushley S, Duncan HF, Lappin MJ, Tomson PL, Lundy FT, Cooper P, *et al*. Pulpotomy for mature carious teeth with symptoms of irreversible pulpitis: a systematic review. *Journal of Dentistry*. 2019; 88: 103158.
- [10] Lin GSS, Yew YQ, Lee HY, Low T, Pillai MPM, Laer TS, *et al*. Is pulpotomy a promising modality in treating permanent teeth? An umbrella review. *Odontology*. 2022; 110: 393–409.
- [11] Tewari N, Goel S, Mathur VP, O’Connell AC, Johnson RM, Rahul M, *et al*. Success of medicaments and techniques for pulpotomy of primary teeth: an overview of systematic reviews. *International Journal of Paediatric Dentistry*. 2022; 32: 828–842.
- [12] Akbulut MB, Mutlu ŞN, Soylu MA, Şimşek E. Interfacial characteristics of BIOfactor MTA and Biodentine with dentin. *Microscopy Research and Technique*. 2023; 86: 258–267.
- [13] Taha NA, Al-Rawash MH, Imran ZA. Outcome of full pulpotomy in mature permanent molars using 3 calcium silicate-based materials: a parallel, double blind, randomized controlled trial. *International Endodontic Journal*. 2022; 55: 416–429.
- [14] Duncan HF, El-Karim I, Dummer PMH, Whitworth J, Nagendrababu V. Factors that influence the outcome of pulpotomy in permanent teeth. *International Endodontic Journal*. 2023; 56: 62–81.
- [15] Lee S, Park Y, Setzer FC. Combined regenerative and vital pulp therapies in an immature mandibular molar: a case report. *Journal of Endodontics*. 2020; 46: 1085–1090.
- [16] Philip N, Suneja B. Minimally invasive endodontics: a new era for pulpotomy in mature permanent teeth. *British Dental Journal*. 2022; 233: 1035–1041.
- [17] Ather A, Patel B, Gelfond JAL, Ruparel NB. Outcome of pulpotomy in permanent teeth with irreversible pulpitis: a systematic review and meta-analysis. *Scientific Reports*. 2022; 12: 19664.
- [18] Lin LM, Ricucci D, Saoud TM, Sigurdsson A, Kahler B. Vital pulp therapy of mature permanent teeth with irreversible pulpitis from the perspective of pulp biology. *Australian Endodontic Journal*. 2020; 46: 154–166.
- [19] Chen Y, Chen X, Zhang Y, Zhou F, Deng J, Zou J, *et al*. Materials for pulpotomy in immature permanent teeth: a systematic review and meta-analysis. *BMC Oral Health*. 2019; 19: 227.
- [20] Ahmed MI, El Hilaly Mohamed Eid G, Youssef HA. Clinical and radiographic assessments of potassium nitrate in polycarboxylate versus mineral trioxide aggregate as pulpotomy biomaterials in immature

- mandibular first permanent molars: a randomized clinical trial. *Journal of Endodontics*. 2021; 47: 1672–1682.
- [21] Abuelniel GM, Duggal MS, Duggal S, Kabel NR. Evaluation of mineral trioxide aggregate and biodentine as pulpotomy agents in immature first permanent molars with carious pulp exposure: a randomised clinical trial. *European Journal of Paediatric Dentistry*. 2021; 22: 19–25.
- [22] Minic S, Florimond M, Sadoine J, Valot-Salengro A, Chaussain C, Renard E, *et al.* Evaluation of pulp repair after BiodentineTM full pulpotomy in a rat molar model of pulpitis. *Biomedicines*. 2021; 9: 784.
- [23] Zafar K, Jamal S, Ghafoor R. Bio-active cements-mineral trioxide aggregate based calcium silicate materials: a narrative review. *Journal of the Pakistan Medical Association*. 2020; 70: 497–504.
- [24] Palczewska-Komsa M, Kaczor-Wiankowska K, Nowicka A. New bioactive calcium silicate cement mineral trioxide aggregate repair high plasticity (MTA HP)—a systematic review. *Materials*. 2021; 14: 4573.
- [25] Rezende TMB, Ribeiro Sobrinho AP, Vieira LQ, Sousa MGDC, Kawai T. Mineral trioxide aggregate (MTA) inhibits osteoclastogenesis and osteoclast activation through calcium and aluminum activities. *Clinical Oral Investigations*. 2021; 25: 1805–1814.
- [26] Leme KSV, Salvadori DMF. *In vitro* toxicogenomic activity of an MTA/salicylate-based endodontic sealer. *Toxicology Reports*. 2022; 9: 1076–1081.
- [27] Pednekar A, Ataide I, Fernandes M, Lambor R, Soares R. Spectrophotometric analysis of coronal discolouration induced by ProRoot MTA, Biodentine and MTA repair HP used for pulpotomy procedures. *European Endodontic Journal*. 2021; 6: 189–196.

How to cite this article: Han Qin, Jun Cai. Clinical evaluation of permanent molars diagnosed by irreversible pulpitis with apical periodontitis treated by MTA pulpotomy. *Journal of Clinical Pediatric Dentistry*. 2025; 49(1): 97-104. doi: 10.22514/jocpd.2025.009.