

## Skeletal maturation analysis by morphological evaluation of the cervical vertebrae

Eduardo César Almada Santos\* / Francisco Antônio Bertoz\*\* / Flávia de Moraes Arantes\*\*\* / Patrícia Maria Pizzo Reis\*\*\*\* / André Pinheiro de Magalhães Bertoz\*\*\*\*\*

*The determination of skeletal maturation by morphological evaluation of the cervical vertebrae was evaluated in a 100 cephalograms. The analysis showed that this method was reproducible for assessing the individual's growth curve.*

J Clin Pediatr Dent 30(3): 265–270, 2006

### INTRODUCTION

The diagnosis, treatment, prognosis, and stability of the results have become more precise with the development of the contemporary orthodontics. This situation is characterized by the dental movements to influence growth and subsequent relationship in the apical bases: maxilla or mandible.<sup>22</sup>

The orthodontic movement, represented by the displacement of the tooth, can be performed independently of age, as long as the mechanotherapy respects the biology of the periodontium. However, the repositioning of the apical bases in the correction of the skeletal discrepancies with orthopedic appliances needs the support of the facial growth. So, the treatment with orthopedic objectives is best performed while the forces of the physiological growth are active.<sup>22</sup> Early treatment is extremely important to attain a

satisfactory outcome. Prepubertal growth period is the best time to start orthopedic treatment of skeletal malocclusions, because it is a favorable phase for craniofacial alterations coordinating orthopedic-orthodontic procedures.<sup>17,19,20</sup>

The determination of the growth peak contributes to the elimination of probable interferences<sup>17</sup> with the use of appliances and proper techniques, guiding and favoring dentoskeletal relations. The decisions as to the use of the functional appliances, the orthodontic treatment with or without extractions, and the time of the orthognathic surgery are specially based in considerations as to the present stage of skeletal maturation of the patient.<sup>3,10,16</sup>

The ideal time to start an orthodontic treatment is a controversial topic in literature.<sup>23,25,26</sup> Recent articles reflect the debates and offer a number of opinions on early treatment,<sup>23,24</sup> performed into two phases (orthopedics and corrective orthodontics) versus late treatment, performed in a single phase (corrective orthodontics).

Besides the chronological age, there are many biological parameters, which can determine the stage of the subject is in the growth curve, the dental age, circumpuberal age, (the one that takes into consideration the appearance of the secondary sexual characteristics), the relationship of height-weight and the skeletal age.<sup>11</sup> The skeletal age represents the most reliable means and the most utilized method at the moment.<sup>11,19,20</sup> Others present greater deviations when compared to the standard average and the variation of time, duration and velocity from person to person. These deviations and variations are due to genetic and racial questions,<sup>8,18</sup> climate conditions, nutritional circumstances, socioeconomic conditions, alterations of an earlier maturation of man along the time (secular alterations) and hormonal and sexual questions.<sup>8,17</sup>

Various methods are used for the determination of

\* Eduardo César Almada Santos, DDS, MSc, PhD, Doctor Assistant Professor of Orthodontics Discipline in Social and Children Department at Araçatuba Dental School, UNESP.

\*\* Francisco Antônio Bertoz, DDS, MSc, PhD, Doctor Assistant Professor of Orthodontics Discipline in Social and Children Department at Araçatuba Dental School, UNESP.

\*\*\* Flávia de Moraes Arantes, DDS, Trainee of Orthodontics Discipline at Araçatuba Dental School, UNESP.

\*\*\*\* Patrícia Maria Pizzo Reis, DDS, MSc, Master in Dentistry, Orthodontic area of Araçatuba Dental School, UNESP.

\*\*\*\*\* André Pinheiro de Magalhães Bertoz, DDS, MSc, Master in Dentistry, Orthodontic area of Araçatuba Dental School, UNESP.

Send all correspondence to:

Dr. Eduardo César Almada Santos (Discipline of Orthodontics) José Bonifácio, St., 1193, Araçatuba Dental School, UNESP, Araçatuba, São Paulo, Brazil, Zip code: 16015-050

Voice: 018-3636-3236/ 018-8112-5555

E-mail: almada@foa.unesp.br

the skeletal maturation, such as the use of carpal radiographs,<sup>8,9</sup> radiographs of the thumb<sup>22</sup> and the evaluation by means of cervical vertebrae.<sup>4,14</sup> Although the carpal radiograph is proven to be efficient and safe, presently, new proposals to evaluate the bony age have been appearing with the intention of reducing the number of radiographic exposures to the patients. Considering that, efforts have been made to employ material routinely used for orthodontic documentation,<sup>4,7</sup> e.g.

cephalogram and the panoramic radiograph. Additionally, these procedures reduce the cost for the patient.

The purpose of this investigation was to determine the feasibility and reproducibility of determining the skeletal maturation for routine clinical application.

#### MATERIALS AND METHODS

The sample was composed of 100 cephalograms of patients presenting for orthodontic treatment at the

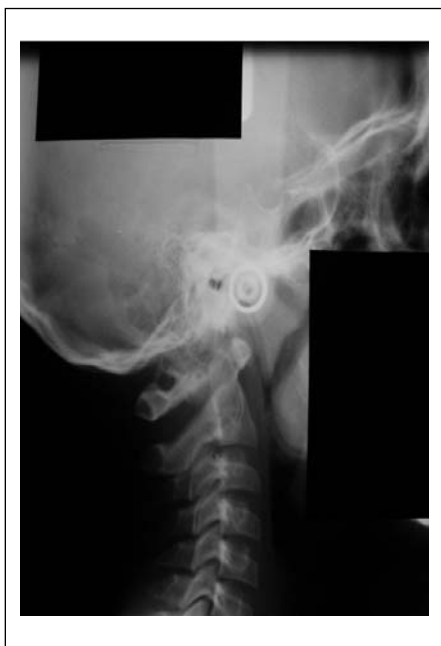

Figure 1. Cephalogram without revealing the identification, age and dental elements of the patient

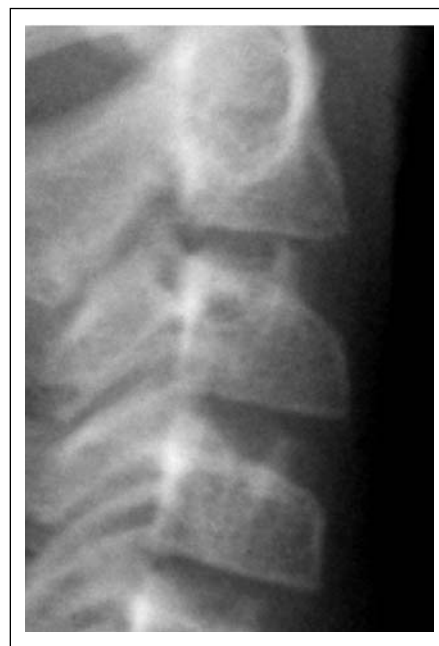

Figure 2. Visualization of the 2nd 3rd and 4th cervical vertebrae in the CVMS I.

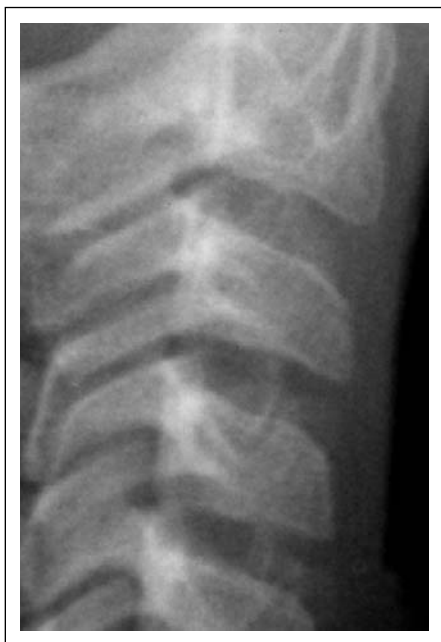

Figure 3. Visualization of the 2nd, 3rd, and 4th cervical vertebrae in the CVMS II.

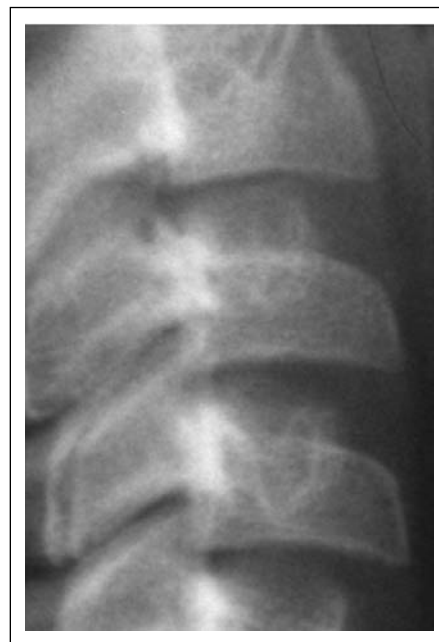
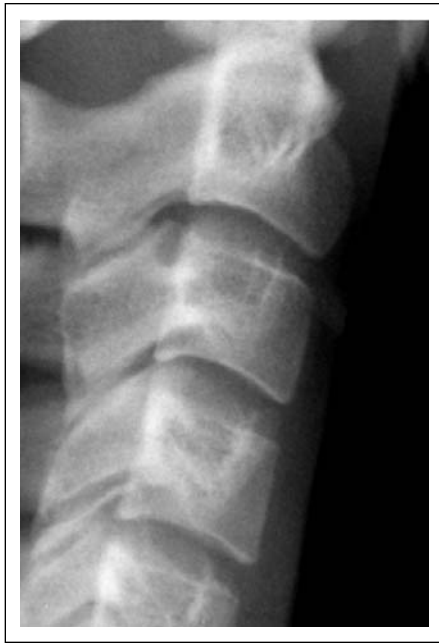
Figure 4. Visualization of the 2nd, 3rd and 4th cervical vertebrae in the CVMS III.



**Figure 5.** Visualization of the 2nd, 3rd, and 4th cervical vertebrae in the CVMS IV.

Faculdade de Odontologia de Araçatuba, UNESP. The sample included both male and female with ages ranging from 6 to 16 years old with the average age of 9 years and 7 months old. The cephalograms were made according to protocol 19 which is recognized by the Discipline of Radiology at UNESP.

The cephalograms were randomized and distributed in envelopes numbered from 1 to 100, without revealing the identification, age and dental elements of the patients to prevent the influence of these factors on the examiners during the evaluation of the skeletal maturational stages.

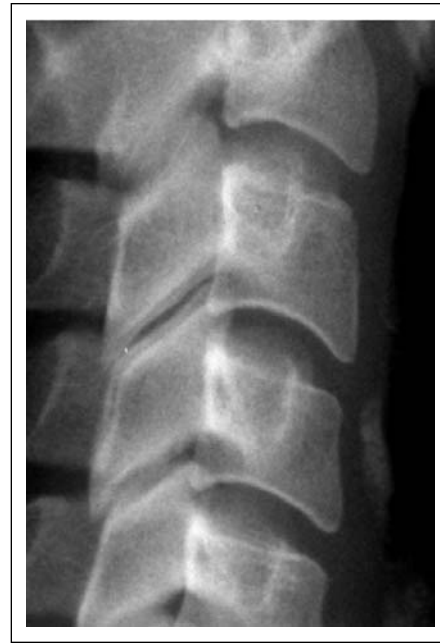#### Method of Skeletal Maturation Evaluation<sup>4</sup>

In 2000, Franchi and Baccetti<sup>4</sup> simplified the method of skeletal maturation evaluation, which consisted in the observation of anatomic modifications of the second, third and fourth cervical vertebral, and divided maturation into 5 stages denominated CVMS (Figures 2 to 7) (Cervical Vertebral Maturation Stage I, II, III, IV, V). It is emphasized that the proposal of this work consists in the verification of feasibility of the Fanchi and Baccetti method.<sup>4</sup>

**Figure 2:** CVMS I. The lower borders of all the three vertebrae are flat, with the possible exception of a concavity at the lower border of C2 in almost half of the subjects. The bodies of both C3 and C4 are trapezoid in shape.

**Figure 3:** CVMS II. A concavity at the lower borders of both C2 and C3 is present. The bodies of both C3 and C4 may be either trapezoid or rectangular horizontal in shape

**Figure 4:** CVMS III. A concavity at the lower bor-



**Figure 6.** Visualization of the 2nd 3rd and 4th cervical vertebrae in the CVMS V.

ders of C2, C3, and C4 is now present. The bodies of both C3 and C4 are rectangular horizontal in shape.

**Figure 5:** CVMS IV. A concavity at the lower borders of C2, C3, and C4 is now present. The bodies of both C3 and C4 are square in shape. If not square, one of the two cervical vertebrae still is rectangular horizontal.

**Figure 6:** VMS V. The concavity at the lower borders of C2, C3 and C4 still is present. The bodies of C3 and/or C4 are rectangular vertical in shape. If not rectangular vertical, one of the two cervical vertebrae still is square.

**Figure 7:** Three examiners performed the evaluation of the cephalogram. The examiners were trained and tested before starting the evaluation of the radiographs. After calibration, they performed the evaluation of the cephalogram for the first time, designated T1. After a period of 15 days, enough time so that the examiners could not remember the markers performed in the initial evaluation, each of them reevaluated all radiographs labeled T2.

The radiographs were evaluated individually by the examiners on a radiographic illuminator in a darkened room. The attained data, then noted down in a sequential page from 1 to 100, was computed using a Kappa coefficient of agreement for the evaluation of intra- and inter-examiners.

#### RESULTS

The level of agreement ranges from 0 to 1<sup>15</sup> (Table 1).

Table 2 refers to the correlation coefficient derived from the comparison of the results of the first and second evaluation of the same examiners, that is, the intra examiner test. The intra examiner results demonstrated a level of agreement almost perfect (examiners A, B

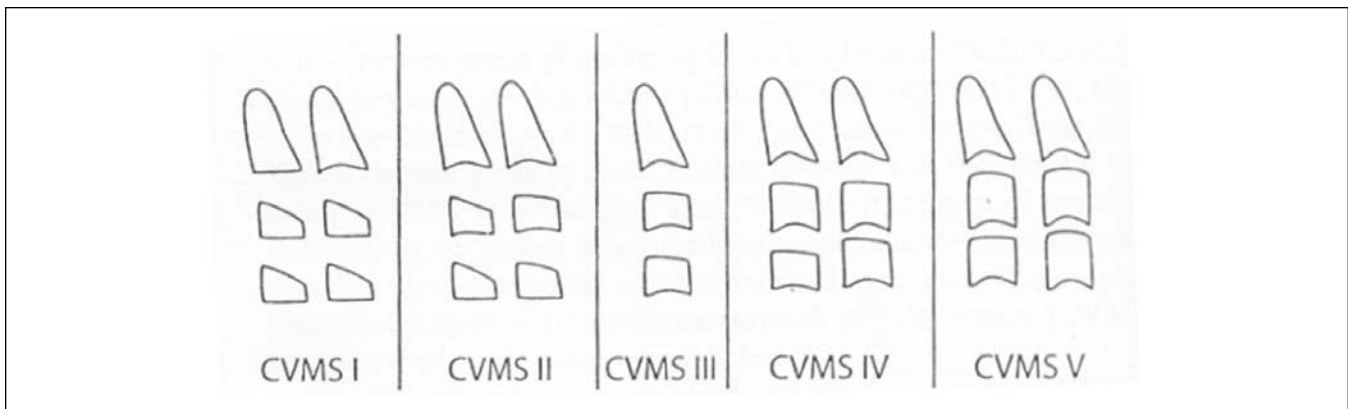


Figure 7. Five maturational stages of the cervical vertebrae according to the Franchi and Baccetti method.

and C).

In Table 3 it is observed that the correlation coefficient

Table 1. Kappa coefficient of agreement with its numeric values and respective agreement levels.

Numeric Variation of the coefficient	Agreement Level
< 0.00	Poor
0.00 – 0.20	Fair
0.21 – 0.40	Reasonable
0.41 – 0.60	Moderate
0.61 – 0.80	Substantial
0.81 – 1.00	Almost Perfect

cient from the comparison of the results among the different examiners, i.e., the inter examiner test. The values indicated a substantial level of agreement for all the comparisons. The high agreement coefficients indicate the possibility of reproducing the method of evaluation, both by the same examiner and by different

Table 2. Kappa coefficient of agreement for the evaluation of the intra examiner test.

Agreement	Percentage (%)	Kappa Coefficient
A1 x A2	91	0.86
B1 x B2	91	0.87
C1 x C2	85	0.79

examiners. A higher agreement level in the intra examiner evaluation when compared with the inter-examiner is expected, demonstrating the reliability in the interpretation of the cases.

Table 2. Kappa coefficient of agreement for the evaluation of the intra examiner test.

Agreement	Percentage (%)	Kappa Coefficient
A x B	86	0.78
A x C	75	0.63
B x C	79	0.7

### DISCUSSION

Considering that the ideal time for the correction of the malocclusions with skeletal deficiencies still remains an issue broadly debated in the contemporary orthodontics,<sup>21-24</sup> the determination of the growth stage and development of the patient, can be a major factor in the choice of the therapeutic approach. The bone age among other biological indicators, is the most faithful form of determining the growth phase of the person. Others<sup>2,12,14,19,20</sup> who utilized the evaluation of the morphology of the cervical vertebrae, verified the efficiency of the proposed method in this work. Recently, Franchi and Baccetti<sup>4</sup> proposed the simplification of the evaluation of the cervical vertebrae. The objective was to make the interpretation of the phase of the patient in the growth curve easier by means of the reducing the stages.

For this reason, we became interested by the reproducibility evaluation and subsequent clinical reliability. The objective is to utilize the radiographic image of the cervical vertebrae in the cephalogram, as it is part of the routine of the orthodontic documentation, while the carpal radiograph would bear an additional radiographic exposure and cost. The use of the cephalogram in determining the skeletal age as well as the usage in treatment, was studied.<sup>1</sup>

For this research, the radiographs were selected from the entries of the patients referred for treatment in the Discipline of Orthodontics at the UNESP, presenting good visualization of the cervical vertebrae. As to the methodology employed in this work, the hiding of the identification was a very relevant factor to prevent the determination of the stage the subject is in the growth curve utilizing the dental and chronological development. The randomized choice of radiographs pertaining to patients ranging from 6 to 16 years, was based in comprising all the maturation stages in the period people look more for orthodontic treatment and with the possibility of utilization of the cranofacial growth. The training, we consider fundamental, was performed by the examiners all together to verify the scores proposed by Franchi and Baccetti,<sup>4</sup> as well as for a standardiza-

tion of the method application. It is considered that the reliability of a method is based on the capacity of being compared by means of intra- and inter-examiner tests with the objective of verifying reproducibility.<sup>19,20</sup>

Accordingly, the analysis of the reliability of the method in this work, primarily the intra-examiner test was performed. Therefore, each one of the examiners analyzed each radiograph twice, in an interval of 15 days. The two series of scores of the three examiners were computed using the Kappa coefficient of agreement. As the percentage of intra-examiner agreement was of 91% for two appraisers (A and B) and 85% for the other (C), the level of agreement was almost perfect, showing the reproducibility of the method by the same professional. The high coefficients of agreement indicate the possibility of reproducing the evaluation method, both by the same examiner, as well by different examiners. The highest level of agreement in the intra-examiner evaluation when compared with the inter-examiner evaluation is expected, demonstrating the reliability in the interpretation of the cases.

The objective is to verify the reliability of the method, one of the two series of scores of each one of the examiners was proved among them, also adopting the Kappa coefficient. It can be concluded that the according to the adopted methodology, the method by Franchi and Baccetti<sup>4</sup> seemed efficient permitting the determination of the skeletal maturation stage of the person with simplicity of identification. This simplicity occurs by the reduction of stages, for the method has only 5 stages and comprises more alterations in the anatomy of the vertebrae in a same phase. Thus, this method can be utilized, after instruction, with the purpose of determination of skeletal maturation stage implying in the clinical choices for treatment, as well as making the prognostic of the results attained more precise with the correction of malocclusions.<sup>13</sup>

## CONCLUSION

It is concluded that the method proposed by Franchi and Baccetti, is reproducible and executable in the determination of the stage the person is in the growth curve. It can be used as an element in the diagnosis and aid in the prognostic of treatment of malocclusions.

## ACKNOWLEDGEMENT

The authors would like to thank FAPESP (Grants n. 02/13556-2) for the financial support to this study.

## REFERENCES

- Almeida MR, Henriques JFC, Almeida RR, Ursi W, McNamara Jr JA. Short-term treatment effects produced by the Herbst appliance in the mixed dentition. *Angle Orthod* 75: 540-547, 2005.
- Armond MC. Estimativa do surto de crescimento puberal pela avaliação das vértebras cervicais em radiografias cefalométricas laterais. 2000. Dissertação (Mestrado) ~ Faculdade de Odontologia de São José dos Campos, Universidade Estadual Paulista „Júlio de Mesquita Filho%, São José dos Campos, 2000.
- Broadbent BH, Golden WH. The value of an assessment of skeletal maturity in orthodontic diagnosis. *Am J Phys Anthropol* 34: 409-410, 1971.
- Franchi L, Baccetti T. The use of maturational indices for the identification of optimal treatment timing in dentofacial orthopedics. Treatment timing: orthodontics for dimensions. *Craniofacial Growth Series. Ann Arbor* 39: 151-170, 2000.
- Franchi L, Baccetti T, Mc Namara Jr JA. Mandibular growth as related to cervical vertebral maturation and body height. *Am J Orthod Dentofac Orthop* 118: 335-40, 2000.
- Franchi L., Baccetti T. An improved version of the cervical vertebral maturation (CVM) method for the assessment of mandibular growth. *Angle Orthod.* 72: 316-323, 2002.
- Franchi L, Baccetti T, Mc Namara Jr, JA. The cervical vertebral maturation method: some need for classification. *Am J Orthod Dentofac Orthop* 19A-20A, 2003.
- Fishman LS. Radiographic evaluation of skeletal maturation: A clinically oriented method based on hand-wrist films. *Angle Orthod*, 52: 88-112, 1982.
- Greulich WW, Pyle SI. Radiographic atlas of skeletal development of hand and wrist. 2.ed. California: Stanford University Press, 1949.
- Uzzi BSS, Carvalho LS. Estudo da maturação óssea em pacientes jovens de ambos os sexos através de radiografias de mão e punho. *Ortodontia* 33: 49-58, 2000.
- Hägg U, Taranger J. Maturation indicators and pubertal growth spurt. *Am J Orthod* 82: 299-309, 1982.
- Hassel B, Farman AG. Skeletal maturation evaluation using cervical vertebrae. *Am J Orthod Dentofac Orthop* 107: 58-66, 1995.
- Houston WJB. Relationships between skeletal maturity estimated from hand-wrist radiographs and the timing of adolescent growth spurt. *Eur J Orthod, Oxford* 2: 81-93, 1980.
- Lamparski DG. Skeletal age assessment utilizing cervical vertebrae. 1972. Dissertação/Abstract, Pittsburgh: University of Pittsburgh, 1972.
- Landis JR, Koch GG. The measurement of observer agreement for categorical data. *Biometrics* 33: 159-174, 1977.
- Martins JCR.; Sakima T. Considerações sobre a previsão do surto de crescimento puberal. *Ortodontia* 10: 164-170, 1977.
- Mercadanti MMN. Radiografia de mão e punho. In: FERREIRA, F.V. *Ortodontia : diagnóstico e planejamento clínico*. 4. ed. São Paulo: Artes Médicas., p. 187-223, 2001.
- Moraes MEL. Surto de crescimento puberal: Relação entre mineralização dentária, idade cronológica, idade dentária e idade óssea: método radiográfico. 1997. Tese (Doutorado em Radiologia Odontológica) ~ Faculdade de Odontologia de São José dos Campos, Universidade Estadual Paulista Júlio de Mesquita Filho, São José dos Campos, 1997.
- Santos SCN, Almeida RR. Estudo comparativo de dois métodos de avaliação da idade esquelética utilizando telerradiografias em norma lateral e radiografias carpais. *Ortodontia* 32: 33-44, 1999.
- Santos SCN, Almeida RR, Henriques JFC, Bertoz FA, Almeida RR. Avaliação de um método de determinação do estágio de maturação esquelética utilizando as vértebras cervicais presentes nas telerradiografias em norma lateral. *Rev Dental Press Ortodont Ortoped Facial* 3: 67-77, 1998.

21. Santos ECA, Henriques JFC. Estudo cefalométrico entre as alterações resultantes de dois tipos de tratamento da má oclusão de Classe II, 1a divisão, de Angle. *Rev Dental Press Ortodon Ortoped Facial* 5: 11-31, 2000.
22. Silva Filho OG, Sampaio LL, Freitas JAS. Avaliação de um método simplificado para estimar a maturação esquelética. *Ortodontia* 25: 21-35, 1992.
23. Tulloch JFC, Proffit WR, Phillips C. Benefit of early Class II treatment: progress report of a two-phase randomized clinical trial. *Am J Orthod Dentofac Orthop*, 113: 62-67, 1998.
24. Tulloch JFC, Proffit WR, Phillips C. Influence on the outcome of early treatment for Class II malocclusion. *Am J Orthod Dentofac Orthop*, 111: 533-542, 1997.

## **Early puberty and adolescent pregnancy: The influence of alcohol use**

Deardoff J. et al. *Pediatrics*. 116, 1451-1456, 2005

The United States has the highest rate of teenage pregnancies among developed nations. It has been shown that, early pubertal onset, behavioral problems, poor self concept, early substance use, early sexual initiation are potential major risk factors for early pregnancy. Girls who mature early enter many times a new world alone, often unprepared cognitively and /or emotionally. They tend to hang with older friends, putting them at a greater risk in engaging in behaviors more typical of older adolescents.

This study from the department of Psychiatry of the University of California, San Francisco and the department of Psychology and Family and Human Development of the University of Arizona, pooled 666 females from the four major ethnic groups, who had experienced a pregnancy in their teens or early 20s.

The authors showed early pubertal girls are more likely to engage in early alcohol use and sexual activities that puts them at a greater risk for adolescent pregnancies.

The authors concluded that preventive screening related to alcohol and sexual initiation education should be enforced.

