

Eruption Disturbances of the Maxillary Incisors: A Literature Review

Kristin L. Huber*/ Lokesh Suri **/ Parul Taneja***

Eruption disturbances can be broadly classified as disturbances related to time and disturbances related to position. Time related disturbances include premature eruption, delayed eruption or impactions. A common feature of these is a significant deviation in eruption time within the established norms for a particular age, sex, race or ethnicity. Although root development represents the fundamental biologic parameter for tooth eruption, chronological age at presentation is used as the first criteria in the establishment of the diagnosis of prematurity or a delay in eruption. Eruption disturbances related to position include ectopic eruption and transpositions. Positional deviations too can cause a delay in eruption time, however, more commonly the involved tooth erupts within the expected time frame with an abnormality in position. The focus of this paper is to present a systematic review of the literature including classification, etiology and treatment modalities available for eruption disturbances of the maxillary incisors.

KEYWORDS: eruption, maxillary, incisor, disturbances
J Clin Pediatr Dent 32(3): 221–230, 2008

INTRODUCTION

The maxillary incisors and canines, often referred to as the ‘social six’, are the most prominent teeth in an individual’s smile. They are also the teeth that are on maximum display during speech in most individuals. The normal eruption, position and morphology of these teeth are crucial to facial esthetics and phonetics. The clinician is often faced with challenging situations where deviations from the normal eruption sequence, position or abnormalities in morphology are observed. Deviations in eruption of the incisors are a frequent clinical presentation. Since eruption has a strong influence on the craniofacial development and incisors are amongst the first teeth to erupt in both the primary and permanent dentition, eruption disturbances of the incisors can be a harbinger of a local or systemic condition. It is essential that the clinician have a thorough knowledge of these eruption disturbances in order to make an

appropriate, as well as timely, intervention for adequate treatment.

PREMATURE ERUPTION

Several authors^{11,12,13} have formulated time tables of the eruption of all teeth based on age, sexual, racial and ethnic denominators and a wide range of variations have been reported. The primary maxillary incisors erupt approximately between the ages of six and nine months and the permanent incisors erupt in the range of six to eight years. Occasionally, the incisors may erupt prematurely from these established norms. Several terms for prematurely erupted primary teeth have been used in the literature, including congenital teeth, fetal teeth, predecidual teeth, and *dentia praecox*. A further distinction has also been made between the natal and neonatal teeth, both of which are prematurely erupted primary incisors. Natal teeth are those that are present in the oral cavity at birth. Neonatal teeth, on the other hand, are those that erupt in the first thirty days of life.¹ Prevalence (Table 2) ranges from 1:716 births to 1:30,000 births, and 11% are maxillary incisors.^{2,3,4,5,6} It is also possible for the permanent incisors to erupt prematurely. This condition causes minimum problems and thus has not been described in the literature.

Etiopathogenesis

The etiology of natal and neonatal teeth is not known, however literature suggests that superficial position of the tooth germ,^{1,2} febrile states,^{1,2} infection or malnutrition,¹ hypovitaminosis,² trauma,² pyelitis,² syphilis,² autosomal dominant gene,^{1,2} precocious bone remodeling around the tooth germ,^{1,7} and hormonal stimulation may play a role.^{2,3,4} Neonatal and

* Kristin L. Huber DMD-Tufts University School of Dental Medicine, Department of Orthodontics

** Lokesh Suri BDS, DMD, MS- Tufts University School of Dental Medicine, Department of Orthodontics

*** Parul Taneja BDS, DMD, MS- Tufts University School of Dental Medicine, Department of Orthodontics

Send all correspondence to: Kristin L. Huber, DMD, Tufts University School of Dental Medicine, 1 Kneeland Street, Boston, Massachusetts 02111

Phone: 404-313-1236

Fax 617-636-2740

E-mail: Lucaskc@hotmail.com

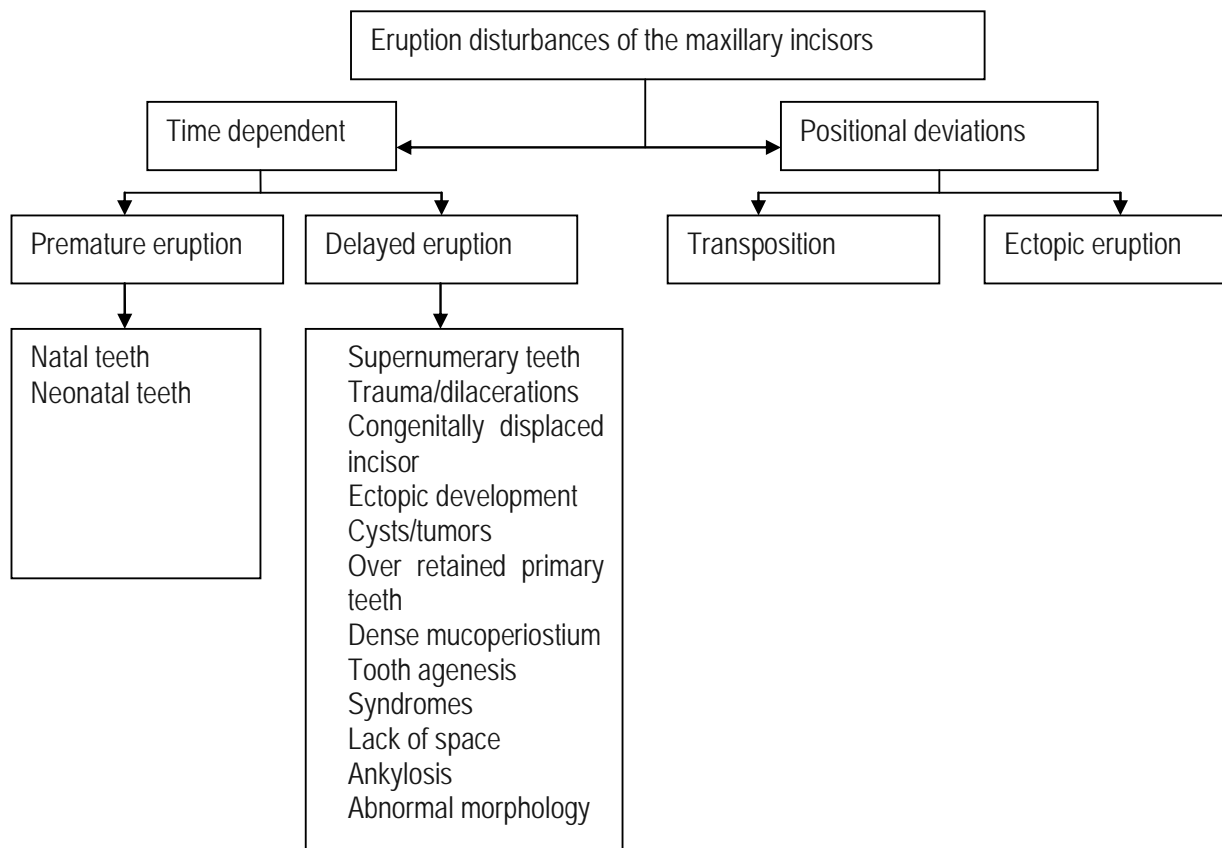


Figure 1.

natal teeth lead to a variety of complications. They often elicit pain resulting in the child refusing to nurse. Enamel spurs or sharp incisal edges may cause ulceration of the tongue. Prematurely erupted mandibular incisors causing ulceration to the ventral surface of the tongue is known as Riga-Fede disease.⁸ Trauma may also occur as a result of sharp edges on maxillary incisors. The teeth often exhibit hypermobility due to the fact that there is no root formation or bony attachment. The tooth is attached only at the cervical gingival. There is a risk that the child may swallow the teeth or they may be aspirated.⁴

Table 1. Eruption disturbances of the maxillary incisors

Premature eruption
Natal teeth
Neonatal teeth
Delayed Eruption / Impaction
Supernumerary teeth
Trauma/dilacerations
Congenitally displaced incisor
Ectopic development
Cysts/tumors
Over retained primary teeth
Dense mucoperiostium
Tooth agenesis
Syndromes
Lack of space
Ankylosis
Abnormal morphology
Ectopic Eruption
Transposition

Treatment

When formulating a treatment plan for prematurely erupted incisors, many factors must be taken into consideration. These include implantation and degree of mobility, inconveniences during suckling, possibility of traumatic injury, and whether the tooth is a part of the normal dentition or is a supernumerary. The maintenance of these teeth in the oral cavity is usually the preferred treatment option, as long as they are not causing difficulty to the infant or the mother. Their removal should only be indicated when they interfere with feeding or when they are highly mobile and pose a risk for aspiration. Riga-fede or trauma is not an absolute reason for extraction. Smoothing down any sharp edges on the tooth can often relieve these conditions. Natal and neonatal teeth that remain in the oral cavity beyond four months of age have a good prognosis.^{1,2} If extraction is the determined course of treatment, it must be followed by curettage of the socket. Careful curettage has been recommended to eliminate any cells of the dental papilla or Hertwig’s root sheath that were detached from the calcified tooth structure during extraction. If these cells remain in the alveolus, they may continue to develop into a tooth-like structure, and may result in an alveolar abscess.²

Although it is more common for primary teeth to erupt prematurely, premature eruption of permanent teeth has also been documented. The Klippel-Trenaunay syndrome is a triad of congenital anomalies characterized by hemangiomas, varicosities, and unilateral bony and soft tissue

Table 2. Prevalence of natal and neonatal teeth reported in the literature

STUDY	Prevalence	Sample Size	Sample Population
Leung (1986) ³	1:3392	50,892	Infants born at the Foothills Provincial Hospital, Calgary, Alberta, Canada,
Rusmah (1991) ⁴	1:2325	9,600	Malaysian infants
To (1991) ⁵	1:1118	53,678	Babies born between January 1984 and December 1988 at Queen Elizabeth Hospital, Hong Kong
Almeida & Gomide (1996) ⁶	1:21.6	1,019	Cleft lip and palate patients, less than 3 months old

Table 3. Prevalence of unerupted or impacted maxillary permanent incisors as reported in the literature

STUDY	Tooth		Sample Size	Sample Population
	Maxillary Central Incisor	Maxillary Lateral Incisor		
Grover and Lorton (1985) ¹¹	0.03%	0.02%	5,000	United States Army recruits ages 17-26
Mead (1930) ¹²	1.96%	0.40%	6,389	Skull analysis of several different races and ages
Kramer and Williams (1970) ¹³	0.96%	0.03%	3,745	Oral Surgery patients at Harlem Hospital, New York

Table 4. Cases of delayed eruption in the presence of supernumerary teeth

STUDY	Percentage of Cases with Delayed Eruption	Sample Size	Sample Population
Gardiner (1961) ²⁰	28%	100	Orthodontic patients at Sheffield Dental School, England
Day (1964) ²¹	39%	80	Oral Surgery patients at Eastman Dental Hospital, England
Howard (1966) ²²	60%	70	Orthodontic patients at King's College Hospital, England
Tay, Pang, Yuen (1984) ²³	26%	204	Hong Kong schoolchildren ages 6.0-9.5 years (mean 7.7 years) 172 males and 32 female
Zilberman, Marlon, Shteyer (1992) ²⁴	52%	100	Jerusalem schoolchildren ages <4 - >10, 72 males and 28 females

hypertrophy. In this syndrome, premature eruption of permanent teeth on the affected side is often seen.⁹ It is also suggested in the literature that premature extraction or loss of a primary incisor may lead to premature eruption of the permanent successor.¹⁰

DELAYED ERUPTION / IMPACTION

A significant delay in eruption from the established norms for various sexes, races and ethnicities has been reported to be more common than premature eruption. The prevalence of delayed eruption specifically related to maxillary incisors can be found in Table 3.^{11,12,13}

Etiopathogenesis

When a patient clinically appears to have delayed eruption of a maxillary incisor, one must consider the possibility of complete tooth agenesis of the incisor. This is more common in the permanent dentition rather than the primary dentition. Permanent tooth agenesis ranges from 1.6%-9.6%.¹⁵ In the

primary dentition, tooth agenesis ranges from 0.5%-0.9%.¹⁵ It is rare for the central incisor to be congenitally missing.²⁹ The prevalence is 0.00-0.01%.¹⁴ However, the maxillary lateral incisor is missing 2.2% of the time.¹⁵ It is the second or third most commonly missing tooth in the dentition. Research has been conducted in the area of genetics in order to determine what role hereditary factors play in tooth agenesis. It has been found that there is a higher incidence of tooth agenesis in women and there are more than sixty inherited syndromes associated with tooth agenesis.¹⁵ Also, it is hypothesized that the phenotype in affected individuals with selective tooth agenesis is due to haploinsufficiency.¹⁶ It appears that peg laterals reflect incomplete expression of a gene defect that causes tooth agenesis and unilateral agenesis may be a result of reduced penetrance.¹⁵

Literature reveals several causes of failure or delayed eruption of maxillary incisors. The most commonly reported cause of eruption delay of the maxillary incisors is the presence of a supernumerary tooth.^{8,17,18,19} The prevalence of

supernumerary teeth varies among the different racial and ethnic groups.^{20,21,22,23,24} (Table 4.) In the Caucasian population, the prevalence is between 1-3%. Of these, 90-98% occur in the premaxilla. Asians have a slightly higher frequency of supernumerary teeth, which is greater than 3%.²³ Black children have a prevalence of supernumerary teeth of 0.42%, while children of Hispanic descent were found to have a prevalence of 5.6%.²⁵ The prevalence of supernumerary teeth also differs between the primary and permanent dentitions. There is no gender predilection in the primary dentition; however, in the permanent dentition, males are affected twice as frequently as females.⁷ The frequency of supernumeraries in the maxillary incisor region is reported to be higher in certain syndromes. This may be as high as 22% in individuals with cleidocranial dysplasia, when compared to the general population.²⁶ Family history can be reviewed to determine the likelihood of a developing child having a supernumerary tooth. It is not the mere presence of a supernumerary tooth that predisposes an individual to delayed tooth eruption. The shape and position are some determining factors that play a role in the fate of the incisors. There are four morphological types of supernumerary teeth: conical or peg-shaped, tuberculate or invaginated, supplemental or incisiform, and odontome-like.^{6,26} The most common type of supernumerary tooth is the conical or peg-shaped⁸ and is more often associated with displacement of the incisors.²⁷ The tuberculate or the invaginated supernumerary has been shown to cause more cases of delayed eruption of the maxillary incisors.^{6,13,17} Tay also found that vertically oriented supernumerary teeth are more likely to be associated with delayed eruption of the permanent incisors.^{7,23}

While supernumerary teeth are the most common cause of delayed eruption of maxillary incisors, eruption failure can also be caused by tooth malformation or dilacerations. Dilacerations occur after trauma to a primary tooth, where the developing permanent tooth bud is damaged due to close proximity to the primary tooth. For this reason, both tooth malformations and dilacerations are more common in the permanent dentition. The degree of damage of the permanent tooth depends on the developmental stage of the tooth in question, as well as the type and direction of the trauma inflicted.^{28,29}

It is important to distinguish a dilacerated incisor from a congenitally displaced incisor during diagnosis.³⁰ The two conditions have similar clinical presentations; however they differ in etiology, treatment and prognosis. As discussed above, the etiology of a dilacerated incisor is a deformation of the developing incisor that occurs as a result of transmitted trauma from a blow to the area or to the primary predecessor. Unlike the dilacerated incisor, the congenitally displaced incisor is morphologically normal, only developing at the wrong site or developed so that its axis of eruption is in the wrong direction. The etiology of a congenitally displaced incisor, although not discussed much in the literature, is believed to be ectopic development, which may indeed cause delayed eruption of the incisor.³⁰ The treatment for congeni-

tally displaced incisors includes applying orthodontic forces so as to change the tooth's angle of inclination from horizontal to vertical. Once this is accomplished, eruption will proceed normally. Prognosis for bringing these teeth into position within the arch is excellent.³⁰

Eruption failure of unerupted incisors may also be attributed to some other morphological and positional variants. DiBiase reported that when a delay in eruption was observed, often the affected incisors had a reduced root formation with an open apex, altered root curvature, labial displacement and labial inclination, as well as mesial/distal displacements/ inclinations.³¹ Ectopic development of the tooth germ, where during root formation the root is molded to match the palatal curve, can also lead to maxillary incisor impaction.¹⁵ The literature also reports that severe malposition and/or impaction against another tooth may inhibit the permanent incisor from erupting.³² These morphological deviations have not been reviewed in the primary dentition.

Eruption failure may also occur if cysts or other pathological obstructions develop in the eruptive path of the incisors.¹⁷ Pathological lesions can occur on the deciduous predecessor or on the permanent tooth itself. The most common developmental lesion encountered in the anterior maxilla, affecting the eruption pattern of the incisors, is the dentigerous cyst.⁹ These cysts are primarily associated with permanent teeth and rarely involve a primary tooth.³³

A delay in eruption specific to the permanent incisors may result from retained primary incisors. This may be caused by the primary tooth becoming ankylosed or non-vital, due to trauma or caries. If the primary roots cannot be resorbed for any reason, the permanent tooth may erupt in an alternate path or not erupt at all. Delayed eruption of both the primary and permanent teeth can also be owing to mucosal barriers in the path of eruption. Formation of a dense mucoperiosteum or submucosa that acts as a physical barrier to eruption can occur during development or following surgery.³²

There are several syndromes that are associated with eruption disturbances specific to the maxillary incisors. These syndromes have a common feature: craniofacial dysmorphogenesis. Holoprosencephaly is a developmental field defect with impaired cleavage of the embryonic forebrain as the cardinal feature.³⁴ The prevalence is about 1 in 11,000-20,000 live births and 1 in 250 during embryogenesis. In mildest forms of Holoprosencephaly, the only manifestation present is the eruption of only one central incisor.³⁴ 18p Syndrome and Congenital nasal pyriform aperture stenosis are also associated with the eruption of a single central incisor. 10% of cases of 18p syndrome are associated with Holoprosencephaly.^{35,36} Kallmann Syndrome is a developmental field defect that is associated with midline defects which include agenesis of the maxillary lateral incisor.³⁷ Rieger syndrome, also called SHORT syndrome, is an autosomal dominant disorder associated with the absence of maxillary incisor teeth.³⁸ Hutchinson-Guilford progeria is a rare genetic condition showing accelerated ageing combined with severe growth retardation. Dental manifestations

include delayed development and eruption of teeth, discoloration, crowding, rotation, and displacement of anterior teeth.³⁹

Literature reveals conflicting opinions on incisor eruption failure due to lack of space in the arch. DiBiase believes that in most cases, as long as space is available, eruption will occur, even if there is significant root curvature. Adequate space is considered to be at least two millimeters greater than the crown of the unerupted incisor.³¹

One may hypothesize that the presence of peg-shaped laterals may have an effect on the eruption patterns of the central incisors. Becker, Gillis, and Shpack⁴⁰ found that missing lateral incisors and peg-shaped lateral incisors have been shown to be associated with palatal displacement of the canine.⁴⁰ No literature was found to support the possibility that similar effects on the maxillary incisors can occur; however, one must entertain the possibility.

Diagnosis

When the incisors do not erupt at the expected time, it is crucial for the clinician to determine the etiology and formulate an appropriate treatment plan. An accurate diagnosis may be obtained after a thorough clinical and radiographic exam. It is also imperative to review a patient's medical history to rule out local or systemic conditions. The dental history provides clinical information about history of trauma.

A visual exam of the adjacent teeth can be very informative in determining the position of the unerupted incisor. One must establish the presence and position of the adjacent teeth, as well as whether the adjacent teeth are upright or inclined towards the missing tooth. This may help in determining the position of the unerupted tooth. If the unerupted incisor is close to its normal eruption position, the teeth may be tilted into the space. When the unerupted incisor is far from its normal eruptive path, the adjacent teeth may begin to close the space with greater bodily movement. The adjacent teeth will remain upright in the latter situation.²⁹ On palpation of the area, the clinician is likely to encounter a palatal or labial bulge that will help determine the position of the unerupted tooth.

To determine the exact position of the unerupted incisor, one must use radiographic interpretation. In almost all cases, more than one radiograph is required.²⁹ One of the classic techniques employed is the parallax method (tube shift method). This method requires the use of two successive periapical radiographs placed in the same position and exposed by an x-ray beam from two different positions.⁴¹ This method was first employed by Clark in 1910, where he used two periapical radiographs and shifted the tube in a horizontal plane. By doing this, the tooth that lies more buccal will move in a direction opposite to that of the x-ray tube. A variation of the horizontal parallax method is the vertical parallax. This method employs the same principle of using two successive periapical radiographs; however, the X-ray tube is shifted in a vertical plane. In 1952 Richards coined the term buccal object rule in order to locate objects on a horizontal plane. Richards found that a change in horizontal

angulation would produce little or no displacement of the two objects. In these cases, it is necessary to shift the x-ray tube in a vertical plane in order to produce significant displacement of the objects.⁴² In 1986, an alternate vertical tube shift method was introduced by Keur where occlusal radiographs are used instead of periapical radiographs. The use of occlusal radiographs allows for greater tube movement, resulting in more displacement of the objects. It also ensures that the entire object in question is captured in the radiograph. Keur also described the use of a combination of an occlusal radiograph and a panoramic.^{42,43} A Panoramic film is useful because it is unique in that it will show the entire dentition as a whole. The vertex occlusal view can be helpful by giving an additional dimension.²⁹ Lateral cephalometric is another film that is particularly useful if there is a supernumerary tooth or dilacerations present because it allows visualization in several dimensions.¹⁷

Although costs may preclude patients from using advanced methods of imaging, the highly detailed information outweighs the high radiation dose, limited availability, and high cost. It has been found that 3D Dental-CT images are superior to conventional radiographs for examining impacted teeth in the maxilla.⁴⁴ In conventional radiographs, the depiction of impacted teeth in the maxilla is often imprecise owing to the confluent images of the hard palate and zygomatic bone. Computerized tomography provides a clear distinction.⁴⁴ It is crucial to determine the exact location of the tooth prior to any surgical procedure. This reduces the damage to surrounding structures and improves the healing process. Due to the highly detailed three-dimension information obtained, computerized tomography is the method of choice for accurately defining the position of an unerupted tooth and identifying any root resorption of adjacent teeth not detectable by other methods.

Digital volume tomography has recently been introduced as an alternate technique to computerized tomography. According to Chaushu *et al*, digital volume tomography has one-sixth of the radiation of computed tomography, is more time efficient, more cost effective, and is still able to provide three dimensional images, excellent bone differentiation, and an unlimited number of views.⁴⁵

Treatment

Although several different approaches to treatment of unerupted maxillary incisors have been proposed in the literature, a common feature among them is that early diagnosis is critical to the success of the treatment.^{11,15} It is thought that the less time the normal eruption is delayed, the better the outcome.^{9,10} If there has been a loss of space, it is necessary to create space prior to treatment and maintain that space throughout the treatment phase.⁴⁶ The treatment possibilities vary from conservative to more aggressive approaches.

The most conservative management would be the extraction of any obstruction, the creation of space, and the observation for spontaneous eruption. Between 54%-74% of teeth have been reported to erupt spontaneously after removal of

obstruction, without any further treatment.¹³ In the case of a supernumerary tooth, it is often possible to remove the supernumerary tooth avoiding damage to the underlying incisor, and allow the incisor to erupt on its own.

In certain cases, orthodontic traction may be required. The surrounding erupted teeth may be used for anchorage to orthodontically move the tooth into the arch following surgical exposure of the unerupted tooth. Patient management can be divided into three phases: pre-surgical orthodontics, exposure and bonding, and post-surgical orthodontics.⁴⁷ In the pre-surgical phase, surrounding teeth that will be used as anchorage must be banded or bonded, and sufficient space must be created for the erupted tooth. It is also necessary to remove any obstruction (i.e. supernumerary tooth). The next step is surgical exposure of the unerupted tooth, which can be done using one of three methods.⁴⁸ A gingivectomy would be the procedure of choice in the presence of attached gingival and if sufficient tooth structure can be exposed to bond an attachment. At least one half to two thirds of the crown must be uncovered. In patients where there is inadequate attached gingiva or if a gingivectomy would compromise the width of attached gingiva, an apically positioned flap is recommended. A third method is the closed eruption technique in which a flap that incorporates the attached gingiva is raised and is fully replaced in its original position after placement of traction devices. If the tooth is impacted in the middle of the alveolus or high in the vestibule near the nasal spine, the closed eruption technique may be the treatment of choice. Some teeth are impacted so high in the vestibule that an apically positioned flap is difficult or impossible to employ.⁴⁹ In all cases, following exposure, isolation of the tooth is required to facilitate bonding. Isolation and hemostasis can be aided by the use of hemostatic agents like Surgical or Gel-Foam around the tooth. The crown is then etched with a phosphoric acid gel that will reduce the chances of the etch running into the adjacent tissues. The area is then rinsed and dried, and a bonding agent is placed. Finally, a bracket is light-cured onto the tooth and a ligature wire or a gold chain is attached to the bracket. In the case of the closed technique, the flap is replaced and sutured into its original position.⁴⁹ Controversy exists regarding the amount of time the clinician should wait to apply post surgical orthodontic forces after exposure and bonding. Some authors recommend application of force immediately after exposure.¹ Others recommend waiting for one⁴⁹ to two weeks.⁵¹ This decision appears to be the personal preference of the clinician. It has been reported that treatment of unerupted maxillary incisors with the closed-eruption technique can produce overall good long-term esthetic results.⁴⁸

Literature supports DiBase's hypothesis that as long as there is sufficient space available, a tooth will erupt on its own. However, contemporary orthodontics has several techniques available to expedite this process. An alternative to mechanical traction is the use of magnetic traction.⁵² Magnets used in orthodontics are neodymium-iron-boron and produce static magnetic fields. Magnets that contain neodymium only were found to be susceptible to corrosion

in the presence of oral fluids, which results in the release of potentially harmful products. The magnets are coated with parylene (poly-para-xylene) in thin sections to prevent corrosion.⁵³ Research shows that the static magnetic fields produced by orally placed orthodontic rare earth magnets do not result in any change in pulp or gingival tissue adjacent to the magnets.⁵⁴ The technique for the use of magnets for tooth eruption involve using Fuji Ortho LC⁵⁵ to bond a 3x3x1mm neodymium-iron-boron magnet to the unerupted tooth and a 5x5x2mm magnet to a removable appliance. During the eruption process, the magnet in the appliance can be changed to precisely direct the movement of the tooth.³⁷ Movement should occur approximately at the rate of one millimeter per month.³⁹ Advantages of using rare earth magnets to aid in tooth eruption include their ability to produce a measured force continuously over long periods of time and the position of the magnet can be manipulated by the clinician so that the tooth can erupt into the ideal position. In addition, few adjustments are necessary throughout the entire process as opposed to the frequent adjustments of mechanical devices. Disadvantages include the fact that the force between two magnets diminishes dramatically as the distance increases. Heat and hot liquids cause the magnets to lose flux, and therefore lose force. Finally, the corrosive properties of neodymium-iron-boron are a disadvantage.³⁷

Orthodontic traction may have no effect on bringing the tooth into occlusion if the unerupted tooth has been ankylosed. The possibility exists for an erupting incisor to become ankylosed at some point during the eruption process. There is limited literature regarding treatment in such a situation; however, literature was found regarding treatment of an ankylosed incisor resulting from trauma. Ankylosis occurs when replacement resorption occurs at the innermost layer of the periodontal ligament and possibly at the cementum. The healing process takes place from the adjacent alveolar bone causing ankylosis.⁵⁶ In situations where a portion of the clinical crown is exposed, early clinical diagnosis includes percussion tests where there is a change in the percussion sound and a marked decrease in the normal physiologic facial-lingual excursion.⁵⁶ The clinician must be cautious in using percussion sounds as a method of diagnosis. One must not ignore the possibility of a false negative.⁵⁷ In situations where the incisor is still unerupted and is completely submerged, percussion would be impossible. When an incisor has been intruded with resulting ankylosis, the clinician can attempt surgical luxation to break the ankylosis while maintaining periapical blood supply at the same time. This results in an inflammatory reaction that encourages the formation of a new fibrous ligament. Immediate application of orthodontic forces is then placed to prevent the reoccurrence of ankylosis. This technique has limited benefits because re-ankylosis in a luxated tooth, even with immediate orthodontic forces, is frequently seen.⁵⁸ Chaushu, Becker, and Chaushu suggest certain guidelines for successful ortho-surgical treatment of an ankylosed tooth. First, proper surgical luxation should be performed which results in class 3 tooth mobility. Second, a heavy extrusive force

should be promptly applied. Third, the extrusive force should be maintained at an appropriately high level by frequently renewing the elastic force.⁵⁹ Distraction osteogenesis, a technique for forming new bone through bone transport,⁶⁰ is also well described in the literature. After surgery, a distraction device is placed. These devices can range from a conventional acrylic splint and an expansion screw that is bonded to the ankylosed incisor,⁵⁶ to a single tooth distractor that is surgically placed.⁶⁰ A latency period is required prior to initiation of the distraction phase. Controversy exists on the length of the latency period and the rate of distraction. Koford, Wurtz, and Melsen propose a latency period of 4 days and a rate of distraction of 0.9 millimeters a day.⁵⁶ Kinzinger *et al* recommend a latency period of 7 days and a rate of distraction of 0.6 millimeters a day.⁶⁰ It is mentioned that vertical distraction could possibly be functionally and esthetically unsatisfactory because of the unidirectional impact of intraoral distraction devices.⁶⁰ It is possible that distraction devices need to be used in conjunction with other approaches.

If an impacted incisor is associated with a cyst, a conservative approach is preferred in order to prevent the loss of the incisor. When the preservation of the tooth is desired in a young patient where the lesion is isolated, marsupialization is the treatment of choice. Marsupialization is a procedure that involves the creation of a surgical window in the wall of the cyst. The cystic lining is made continuous with the oral cavity. The opening must be maintained artificially to prevent spontaneous closure. The cyst remains open for several months allowing the cavity to be filled with new bone. The involved teeth are then allowed to spontaneously erupt or are orthodontically brought into the correct position. By utilizing marsupialization, treatment is atraumatic and can prevent psychological and mental trauma.⁶¹

A final treatment option, which should only be used in cases when the unerupted incisor is severely ectopic or if there is extensive pathology and/or risk to adjacent teeth, is extraction of the unerupted incisor.⁶² In the case of a dilacerated tooth with an extremely acute angle of dilacerations, it is possible for the labially oriented portion of the root to become impacted on the buccal cortical plate. For this reason, dilacerated incisors are often extracted.³⁰ It is essential that care be exercised to avoid damage to adjacent teeth during removal. The surgeon also should take precautions to avoid loss of alveolar bone that could adversely affect future treatment possibilities including replacement with a bridge, implant, or orthodontic space closure.³²

Complications of treatment

When considering surgical treatment of young children, the psychological ramifications of the surgery must be considered. A study was performed in 2005 evaluating patients' perceptions of recovery after exposure of impacted teeth using a closed-eruption technique. The study concluded that regardless of the surgical method used to expose an impacted tooth, it is reasonable to assume that it will have an adverse influence on several aspects of health related quality

of life. Patients should expect recovery within three days of surgery and should be able to return to school within four to six days post-operatively. It was found that a surgical exposure that exceeds thirty minutes resulted in an increase of post-operative pain. It has also been reported that exposure of buccally impacted teeth have a longer recovery period than exposure of palatally impacted teeth.⁵⁰

It is also important to select an appropriate flap design prior to the surgical procedure. One of the flap designs used to expose the unerupted incisor is the apically repositioned flap. This design has the advantage of ensuring a band of attached gingiva around the crown, as well as applying downward tension during suturing. This initiates immediate occlusal movement of the incisor. It also allows for control of the amount of keratinized tissue present post-surgically, which helps to maintain the mucogingival complex around the exposed tooth.⁶³ This ensures a healthy long term periodontal prognosis of the tooth. Conversely, this flap design may result in poor esthetics including an increased crown height and gingival scarring.^{14,64} Due to the anterior position of the incisors, one may choose to use another method, such as closed eruption technique to prevent the aforementioned problems.

Another possible complication in treatment is damage to the adjacent teeth during surgical procedures.⁹ During the early mixed dentition stage, children have several teeth that are in crucial developmental and eruption stages. Disruption to these teeth could cause more problems for the child in the future. One must also use caution when traction is being used to bring the unerupted incisor into position. It has been reported that application of excessive force may result in pulpal necrosis.⁹

Periodontal problems can be a complication of surgical treatment. This includes the loss of keratinized tissue, gingival recession, and poor oral hygiene during orthodontia. Periodontal complications are more common with buccally displaced unerupted teeth than with the palatal ones.⁶⁵ Any mucogingival intervention should be aimed at maintaining an adequate zone of keratinized tissue, in order to prevent gingival recession.

Risks of no treatment

If left untreated, an unerupted incisor can lead to esthetic and pathological problems. If the space is ignored, mesial movement of neighboring teeth will occur, causing obliteration of the space. If the incisor is not brought into occlusion or extracted, resorption of the roots of adjacent teeth may occur.¹¹ Other possible sequela include cyst formation, ankylosis, external tooth resorption, and periodontal problems. Data shows that an impacted central incisor may have significant effects on the path of ipsilateral canine and can lead to canine impaction.⁶⁶ In the presence of an impacted central incisor, the adjacent lateral incisor is displaced by approximately five millimeters. The lateral incisor therefore alters its relationship in regards to the canine, which is at a crucial stage of development. Thus, an alteration in the mesial or buccal position of the canine may result.⁶⁶ Socially, it is

extremely difficult for a young child to go through prepubertal and pubertal years with a space in the anterior maxilla. Such a condition may delay the child's social adjustment among his or her peers and ultimately affect his or her quality of life.

ECTOPIC ERUPTION

Etiopathogenesis

Ectopic eruption refers to the eruption of a tooth in a position that is not its normal position in the dental arch. Theories have attempted to explain the etiology of ectopic eruption. However, the multifactorial process of growth and development makes it difficult to identify specific primary etiological factors of ectopic eruption.⁶⁷ The prevalence of ectopic eruption is 5.6%. The majority of these are permanent central incisors. There is no evidence of sex predilection. In the maxilla, ectopia is more often unilateral, as opposed to the mandible where ectopic eruption is usually bilateral.⁶⁸

Treatment

Depending on the position of the ectopic incisor, various treatment options exist. If there is minimal deviation from the normal eruptive position, it may be possible to extract the corresponding primary incisor and allow the incisor to find its way into normal position.⁶⁹ If the ectopic incisors need assistance to be brought into the correct position, an appliance can be used. An example would include a 2X4.⁷⁰ The 2 X 4 fixed bracketing technique is comprised of brackets on the maxillary incisors, bands on the first permanent maxillary molars, and a continuous archwire. It is used in the early mixed dentition for treatment of both anterior crossbites and alignment of ectopic incisors. This technique offers many advantages as it provides complete control of anterior tooth position, is extremely well tolerated, requires no adjustment by the patient, and allows accurate and rapid positioning of the teeth.⁷⁰ Care must be taken to avoid untorquing the permanent lateral permanent incisors (ugly duckling stage) and prevent possible root resorption of the laterals against the crown of the unerupted permanent canines. If it were not possible to bring an ectopically erupted incisor into position, extraction may be necessary.

TRANSPPOSITION

Tooth transposition is defined as the positional interchange of two adjacent teeth, especially their roots, or the development or eruption of a tooth in a position occupied normally by a non-adjacent tooth. Although on initial presentation transposition may clinically appear to be delayed eruption, a thorough history and clinical examination will prove otherwise. It can be a severe disturbance of tooth order and eruptive position. Transposition of maxillary teeth occurs in approximately 1 in 300 patients. Normal eruption of maxillary incisors can be affected either indirectly or directly. If surrounding teeth are transposed, root anatomy of lateral or

central incisors can be damaged and eruption can be delayed. If an incisor is transposed with another tooth, such as the canine, the patient will usually seek treatment for an unerupted incisor.⁷¹

Etiopathogenesis

Although several theories have been presented, the etiology of tooth transpositions is still unknown. A potential explanation is that transposition occurs as a result of interchange in location between the anlage of the developing teeth.⁷² Trauma to the primary dentition with subsequent permanent tooth drift has also been reported as a likely cause to transposition.⁷¹ It has also been suggested that over retention of primary teeth may displace the developing permanent tooth from its eruptive path.

Treatment

In the maxillary arch, if possible, the transposed teeth should be moved into their normal positions. This can only be accomplished if there is an incomplete transposition where the crowns are transposed, but the root apices are in their normal position. This will result in the most esthetically and functionally sound outcome. When there is a complete transposition, and the root apices have been transposed along with the crowns, the best treatment option is alignment of the teeth in their transposed position.⁷² At this time, the teeth can be improved esthetically with restorative procedures.⁷¹

CONCLUSION

It is not uncommon for children to present with variations in normal eruptive patterns of the maxillary incisors. By virtue of the location of the maxillary incisors, parents are often discouraged when eruption patterns do not follow the norms. This will usually prompt the parent to seek treatment from an orthodontist in order to prevent psychological ramifications that accompany abnormalities of the anterior maxilla. In order to properly treat these individuals, the clinician must have knowledge of the classification, etiology, and treatment modalities available for eruption disturbances of the maxillary incisors. It is important that a thorough examination is performed in order to obtain an accurate diagnosis. The clinical presentations of these eruption disturbances may prove to be a manifestation of an underlying local or systemic condition. In many cases, there may be no treatment necessary except for the creation of space and allowing the tooth to erupt alone in a matter of time. Other cases require surgical and/or orthodontic interception. Each case must be treated independently in order to formulate the proper treatment plan and to achieve the best possible outcome for each patient.

REFERENCES:

1. Cunha RF, Boer FA, Torriani DD, Frossard WTG. Natal and neonatal teeth: review of the literature. *Pediatr Dent*, 2: 23, 2001.
2. Zhu J, King D. Natal and neonatal teeth. *J Pediatr Dent Child*, 62: 123-128, 1995.
3. Leung AK. Natal teeth. *Am J Dis Child*, 140: 249-251, 1986.

4. Rusmah M. Natal and neonatal teeth: a clinical and histological study. *J Clin Pediatr Dent*, 15: 251–253, 1991.
5. To EW. A study of natal teeth in Hong Kong Chinese. *Int. J. Pediatr Dent*, 1: 73–76, 1991.
6. vi de Almeida CM, Gomide MR. Prevalence of natal/neonatal teeth in cleft lip and palate infants. *Cleft Palate-Craniofac J*, 33: 297–299, 1996.
7. vii Jasmin JR, Clergeau-Guerithault S. A scanning electron microscopic study of the enamel of neonatal teeth. *J Biologie Buccale*, 19: 309–314, 1991.
8. Buchanan S, Jenkins CR. Riga-Fedes syndrome: natal or neonatal teeth associated with tongue ulceration. Case report. *Aust Dent J*, 42: 225–227, 1997.
9. Mueller-Lessmann V, Behrendt A, Wetzell WE, Petersen K, Anders D. Orofacial findings in the Klippel-Trenaunay syndrome. *Int J Pediatr Dent*, 11: 225–229, 2001.
10. Holan G, Topf J, Fuks AB. Effect of root canal infection and treatment of traumatized primary incisors on their permanent successors. *Endodontics & Dent Traumatology*, 8: 12–15, 1992.
11. Grover PS, Lorton L. The incidence of unerupted permanent teeth and related clinical cases. *Oral Surg., Oral Med Oral Pathol*, 59: 420–425, 1985.
12. Mead S.V. Incidence of Impacted Teeth. *Int. Orthod*, 16: 885–890, 1930.
13. Kramer RM, Williams AC. The incidence of impacted teeth. A survey at Harlem hospital. *Oral Surg., Oral Med., Oral Pathol*, 29: 237–241, 1970.
14. Polder BJ, Van't Hof MA, Van der Linden FPGM, Kuijpers-Jagtman AM. A meta-analysis of the prevalence of dental tooth agenesis of permanent teeth. *Community Dent Oral Epidemiol*, 32: 217–226, 2004.
15. Vastardis H. The genetics of human tooth agenesis: new discoveries for understanding dental anomalies. *Am J Orthod Dentofac Orthop*, 117: 650–656, 2000.
16. Hu G, Vastardis H, Bendall AJ, Wang Z, Logan M, Zhang H, Nelson C, Stein S, Greenfield N, Seidman CE, Seidman JG, Abate-Shen C. Haploinsufficiency of *MSX1*: a mechanism for selective tooth agenesis. *Mol. & Cell. Biol*, 18: 6044–6051, 1998.
17. Bodenham RS. The treatment and prognosis of unerupted maxillary incisors associated with the presence of supernumerary teeth. *Brit Dent J*, 123: 173–177, 1967.
18. Munns D. Unerupted incisors. *Brit J Orthod*, 8: 39–42, 1981.
19. Bishara SE. Treatment of unerupted incisors. *Am J Orthod*, 59: 443–447, 1971.
20. Gardiner, JH. Supernumerary teeth. *Dent Pract (Epsom)*, 12: 63–73, 1961.
21. Day, RCB. Supernumerary Teeth in the Premaxillary Region. *Brit Dent J*, 116: 304–308, 1964.
22. Howard RD. The unerupted incisor. A study of the postoperative eruptive history of incisors delayed in their eruption by supernumerary teeth. *Dent Pract Dent Record*, 17: 332–341, 1967.
23. Tay F, Pang A, Yuen S. Unerupted maxillary anterior supernumerary teeth: report of 204 cases. *J Dent for Child*, 51: 289–294, 1984.
24. Zilberman Y, Malron M, Shteyer A. Assessment of 100 children in Jerusalem with supernumerary teeth in the premaxillary region. *J Dent Child*, 59: 44–47, 1992.
25. Barton DH, Murray C. Ethnic and racial relationships and supernumerary teeth in the primary dentition. *J Indiana Dent Assoc*, 56: 32–33, 1977.
26. Garvey MT, Barry HJ, Blake M. Supernumerary teeth—an overview of classification, diagnosis and management. *J Can Dent Assoc*, 65: 612–616, 1999.
27. Mitchell L, Bennett TG. Supernumerary teeth causing delayed eruption—a retrospective study. *Brit J Orthod*, 19: 41–46, 1992.
28. Chew MT, Ong MM. Orthodontic-surgical management of an impacted dilacerated maxillary central incisor: a clinical case report. *Pediatr Dent*, 26: 341–344, 2004.
29. Brin I, Zilberman Y, Azaz B. The unerupted maxillary central incisor: review of its etiology and treatment. *J Dent Child*, 49: 352–356, 1982.
30. Howard RD. The congenitally displaced maxillary incisor: a differential diagnosis. *Trans Brit Soc for the Study of Orthod*, 5: 31–41, 1969–1970.
31. Di Biase DD. The effects of variations in tooth morphology and position on eruption. *Dent Pract Dent Record*, 22: 95–108, 1971.
32. Jones JW, Husain J. Management of the unerupted incisor. *Dent Update*, 23: 36–39, 1996.
33. Neville BW, Damm DD, Allen CM, Bouquet JE. *Oral and maxillofacial pathology*. Philadelphia: W.B. Saunders; 2002.
34. Moog U, De Die-Smulders CE, Schrandt-Stumpel CT, Engelen JJ, Hamers AJ, Frints S, Fryns JP. Holoprosencephaly: the Maastricht experience. *Genet Counseling*, 12: 287–298, 2001.
35. Dolan LM, Willson K, Wilson WG. 18p - syndrome with a single central maxillary incisor. *J Med Genetics*, 18: 396–398, 1981.
36. Van Den Abbeele T, Triglia JM, Francois M, Narcy P. Congenital nasal pyriform aperture stenosis: diagnosis and management of 20 cases. *Ann Otol Rhinol and Laryngol*, 110: 70–75, 2001.
37. de Zegher F, Lagae L, Declercq D, Vinckier F. Kallmann syndrome and delayed puberty associated with agenesis of lateral maxillary incisors. *J Craniofac Genetics and Develop Biol*, 15: 87–89, 1995.
38. Slavkin HC. Rieger syndrome revisited: experimental approaches using pharmacologic and antisense strategies to abrogate EGF and TGF-alpha functions resulting in dysmorphogenesis during embryonic mouse craniofacial morphogenesis. *Am. J. Med. Genetics*, 47: 687–697, 1993.
39. Batstone MD, Macleod AW. Oral and maxillofacial surgical considerations for a case of Hutchinson-Gilford progeria. *Int J Pediatr Dent*, 12: 429–432, 2002.
40. Becker A, Gillis I, Shpack N. The etiology of palatal displacement of maxillary canines. *Clin Orthod and Res*, 2: 62–66, 1999.
41. Seward GR. Radiology in General Dental Practice. IX- Unerupted maxillary canines, central incisors, and supernumeraries. *Brit Dent J*, 115: 85–91, 1963.
42. Jacobs, SG. Radiographic localization of unerupted maxillary anterior teeth using the vertical tube shift technique: The history and application of the method with some case reports. *Am J Orthod Dentofac Orthop*, 116: 415–423, 1999.
43. Jacobs SG. Radiographic localization of unerupted teeth: Further findings about the vertical tube shift method and other localization technique. *Am J Orthod Dentofac Orthop*, 118: 439–447, 2000.
44. Sawamura T, Minowa K, Nakamura M. Impacted teeth in the maxilla: usefulness of 3D Dental-CT for preoperative evaluation. *Eur J Radiol*, 47: 221–226, 2003.
45. Chaushu S, Chaushu G, Becker A. The role of digital volume tomography in the imaging of impacted teeth. *World J Orthod*, 5: 120–132, 2004.
46. Lester H. Treatment of a case of an unerupted central incisor. *Dent Pract Dent Record*, 19: 320–322, 1969.
47. Oliver RG, Hardy P. Practical and theoretical aspects of a method of orthodontic traction to unerupted teeth illustrated by three cases. *Brit J Orthod*, 13: 229–236, 1986.
48. Becker A, Brin I, Ben-Bassat Y, Zilberman Y, Chaushu S. Closed-eruption surgical technique for impacted maxillary incisors: Apostorthodontic periodontal evaluation. *Am J Orthod Dentofac Orthop*, 122: 9–14, 2002.
49. Kokich VG, Mathews PG. Surgical and orthodontic management of impacted teeth. *Dent Clin North Am*, 37: 181–204, 1993.
50. Chaushu S, Becker A, Zeltser R, Branski S, Vasker N, Chaushu G. Patients perception of recovery after exposure of impacted teeth: a comparison of closed- versus open-eruption techniques. *J Oral Maxillofac Surg*, 63: 323–329, 2005.
51. Crawford LB. Impacted maxillary central incisor in mixed dentition treatment. *Am J Orthod Dentofac Orthop*, 112: 1–7, 1997.
52. Cole BO, Shaw AJ, Hobson RS, Nunn JH, Welbury RR, Meechan JG, Jepson NJ. The role of magnets in the management of unerupted teeth in children and adolescents. *Int J Pediatr Dent*, 13: 204–207, 2003.
53. Noar JH, Evans RD. Rare earth magnets in orthodontics: an overview. *Brit J Orthod*, 26: 29–37, 1999.

54. Bondemark L, Kurol J, Larsson A. Human dental pulp and gingival tissue after static magnetic field exposure. *Eur J Orthod*, 17: 85–91, 1995.
55. Dillingham S. Impacted cuspid treatment with magnets. *Int J Orthod*, 13: 15–17, 2002.
56. Kofod T, Würtz V, Melsen B. Treatment of an ankylosed central incisor by single tooth dento-osseous osteotomy and a simple distraction device. *Am J Orthod Dentofac Orthop*, 127: 72–80, 2005.
57. Duterloo HS. Reliability of diagnostic tests in cases of delayed tooth eruption. *Am J Orthod Dentofac Orthop*, 127: 400–401, 2005.
58. Takahashi T, Takagi T, Moriyama K. Orthodontic treatment of a traumatically intruded tooth with ankylosis by traction after surgical luxation. *Am J Orthod Dentofac Orthop*, 127: 233–241, 2005.
59. Chaushu S, Becker A, Chaushu G. Orthosurgical treatment with lingual orthodontics of an infraoccluded maxillary first molar in an adult. *Am J Orthod Dentofac Orthop*, 125: 379–387, 2004.
60. Kinzinger GS, Janicke S, Riediger D, Diedrich PR. Orthodontic fine adjustment after vertical callus distraction of an ankylosed incisor using the floating bone concept. *Am J Orthod Dentofac Orthop*, 124: 582–590, 2003.
61. Jena AK, Duggal R, Roychoudhury A, Parkash H. Orthodontic assisted tooth eruption in a dentigerous cyst: a case report. *J Clin Pediatr Dent*, 29: 33–35, 2004.
62. Rose JS, Cannell H. Treatment of an inverted unerupted central incisor. *Brit Dent J*, 138: 352, 1975.
63. Ong M, Chew MT. Use of the apically repositioned flap in the management of labially impacted maxillary central incisors. *Singapore Dent J*, 26: 55–59, 2004.
64. Kajiyama K, Kai H. Esthetic management of an unerupted maxillary central incisor with a closed eruption technique. *Am J Orthod Dentofac Orthop*, 118: 224–228, 2000.
65. Kavadia-Tsatala S, Tsalikis L, Kaklamanos EG, Sidiropoulou S, Antoniadis K. Orthodontic and periodontal considerations in managing teeth exhibiting significant delay in eruption. *World J Orthod*, 5: 224–229, 2004.
66. Chaushu S, Zilberman Y, Becker A. Maxillary incisor impaction and its relationship to canine displacement. *Am J Orthod Dentofac Orthop*, 124: 144–150, 2003.
67. Bradley EJ, Bell RA. Eruptive malpositioning of the mandibular permanent lateral incisors: three case reports. *Pediatr Dent*, 12: 380–387, 1990.
68. Kumagai E, Sai S, Nozaka K, Yamada S, Amari E. Clinical study of ectopic eruption of permanent incisors and first molars. *Shoni Shikagaku Zasshi – Jpn J Pedod*, 27: 30–40, 1989.
69. Andreasen JO, Petersen JK, Laskin DM. Textbook and color atlas of tooth impactions: diagnosis, treatment, prevention. Copenhagen: Munksgaard; 1997.
70. McKeown HF, Sandler J. The two by four appliance: a versatile appliance. *Dent Update*, 28: 496–500, 2001.
71. Peck S, Peck L. Classification of maxillary tooth transpositions. *Am J Orthod Dentofac Orthop*, 107: 505–517, 1995.
72. Shapira Y, Kufinec MM. Tooth transpositions—a review of the literature and treatment considerations. *Angle Orthod*, 59: 271–276, 1989.