

## Comparison of Relative Efficacy of Two Techniques of Enamel Stain Removal on Fluorosed Teeth. An *in Vivo* Study

Bharath KP\* / Subba Reddy VV\*\* / Poornima P \*\*\* / Revathy V \*\*\*\* / Kambalimath HV\*\*\*\*\* / Karthik B \*\*\*\*\*

**Objective:** The present study was conducted to compare and evaluate the relative efficacy of enamel microabrasion (using 18% HCl) and bleaching with McInnes solution in the esthetic improvement of fluorosed teeth and to check postoperative sensitivity. **Study design:** 30 children aged between 9-14yrs with a mild or moderate grade of fluorosis as classified according to Dean's fluorosis index and who complained of objectionable esthetics were selected. Split mouth study design was selected in our study. Each subject had one of their maxillary central incisor randomly selected for Enamel microabrasion and the contra lateral maxillary central incisor for McInnes bleaching. Esthetic improvement was assessed by comparing the pre and postoperative digital photographs. During the evaluation session, the pre and postoperative photographs of 30 subjects were incorporated into a power point presentation and were projected side by side in a darkened room. Four calibrated and blinded examiners, including a layman rated the photographs under standardized viewing conditions. Esthetic improvement was assessed for both short and long term improvement. The postoperative sensitivity was recorded for both the procedures immediately after treatment and at one, three and six months intervals. **Results:** The results proved that both immediate and long term (6month) esthetic improvement achieved by McInnes bleaching were superior to enamel microabrasion. There is a reduction in aesthetics of teeth in both the procedures after six months, which was very minimal in McInnes procedure and significant in enamel micro abrasion. Postoperative sensitivity in both techniques were negligible. The sensitivity observed were transient and subsided within an one-month post operatively. None of the subjects reported sensitivity at one, three and six months intervals. **Conclusion:** McInnes bleaching is a better procedure compared to enamel microabrasion in improving the **appearance** of fluorosed teeth. Both techniques are conservative and safe.

**Keywords.** Enamel micro abrasion, McInnes bleaching, Esthetic Improvement.

\* Bharath KP, MDS, Assistant Professor, Department of Pedodontics and Preventive Dentistry, Rishiraj College of Dental Sciences, Bhopal, India.

\*\* Subba Reddy VV, MDS, Former Principal, Professor and Head, Department of Pedodontics and Preventive Dentistry, College of Dental Sciences, Davangere, India.

\*\*\* Poornima P, MDS, Professor and Head, Department of Pedodontics and Preventive Dentistry, College of Dental Sciences, Davangere, India.

\*\*\*\* Revathy V, MDS, Assistant Professor, Department of Pedodontics and Preventive Dentistry, Karpaga Vinayaga Institute of Dental Sciences, Chennai, India.

\*\*\*\*\* Kambalimath HV, MDS, Professor and Head, Department of Pedodontics and Preventive Dentistry, Rishiraj College Of Dental Sciences, Bhopal, India.

\*\*\*\*\* Karthik B, MDS, Assistant Professor, Department of Oral Pathology and Microbiology, Rishiraj College of Dental Sciences, Bhopal, India.

Send all correspondence to: Kashetty Bharath, Department of Pedodontics and Preventive Dentistry, Rishiraj College Of Dental Sciences, Gandhinagar, Bhopal 462036, India.

Tel: +917898519966

E-mail: bha.dentist@gmail.com

### INTRODUCTION

Dental fluorosis is an esthetically objectionable. It can cause a significant psychological impact on a patient. Fluorosis can be as damaging as a facial scar or a birth defect. Ever since the beginning of modern dentistry, dentists have strived to recreate the oral environment to make it more aesthetically pleasing. In the past, restoring teeth with fluorosis could not be performed conservatively. The clinician had to remove several millimeters of tooth structure to place a material with adequate thickness to hide the fluorosis stain. Various methods of therapy have been advocated for the treatment of fluorosis stained teeth. The use of chemical agents to remove enamel stains is not recent. Various chemicals alone or in combination have been used.<sup>1</sup> One of the most popular technique currently in use to improve the cosmetic appearance of fluorosed teeth is enamel micro abrasion. Enamel micro abrasion is a procedure in which a microscopic layer of enamel is simultaneously eroded and abraded with a special compound, leaving a perfectly intact enamel surface behind. Enamel micro abrasion is a simple, yet a conservative technique to eliminate defects such as brown or white opacities, fluorotic discolorations, and decalcified lesions. By repeatedly applying, 18% HCL in a pumice slurry

to the discolored enamel, discoloration gradually disappears. After remineralization, the freshly exposed enamel attains normal color and surface characteristics.

Walter Kane, was the first to describe this treatment in 1916 using 18% HCL liquid, and heat to eliminate brown stain. Modifications of this technique were later developed by Mc.Closkey (18%HCL without heat), Croll, and Cavanaugh (18%HCL and pumice). The latter method has become very popular in recent years<sup>2</sup>. Croll coined the term 'Enamel Microabrasion.'<sup>3</sup> Studies had shown that enamel surfaces treated with microabrasion exhibit a compact and smooth surface. This type of treatment does not weaken the enamel surface but reduces colonization by *streptococcus mutans* and renders the surface more resistant to demineralization.<sup>1</sup>

Teeth discolored by fluorosis can be managed by bleaching, Microabrasion, Veneering, or with artificial crowns. The choice between these, depends on the severity of the disease. However, in more severe cases, the proposed treatment option would be invasive. The problem with invasive treatments is that, most patients demanding treatment for fluorosis, are very young with life expectancy of many decades. The use of prosthetic approach in the form of veneers and crowns results in an excessive sacrifice of tooth material leading to accelerated destruction of teeth at an early age. Furthermore, the restorative approach is time-consuming and relatively expensive. The technology evolution experienced in dentistry offers innovative methods and techniques for maintaining the integrity and health of dental structures. As our culture symbolizes white teeth as a sign of health and success, the vital bleaching has become popular among the dentists, patients and has been shown to be an efficient and safe technique with predictable results. Bleaching has been accepted as the least aggressive method for treating discolored teeth. McInnes technique for removal of fluorosis stains has been shown to be easy, fast and effective. This technique improves the appearance of individual while preserving a tooth structure.

Tooth sensitivity is the most common side effect of both bleaching and micro abrasion. Studies have recorded that, this kind of sensitivity is transient, tends to occur early in treatment and diminishes with time. However, few clinical studies have been done to support this concept. Fluorosis is an endemic condition which requires an ideal treatment option. For teeth affected with fluorosis, the treatment selected should be simple, cost-effective and less time consuming. Enamel micro abrasion and McInnes bleaching are two techniques, which satisfy these criteria.

Thus, the present clinical study was conducted in the Department of Pedodontics and Preventive dentistry to compare and evaluate, the relative efficacy of enamel micro abrasion (using 18% HCL) and bleaching with McInnes solution for the esthetic improvement of fluorosed teeth and to check post operative sensitivity.

### MATERIALS AND METHOD

30 children, aged between 9-14yrs, with dental fluorosis involving their anterior teeth and who met the following inclusion and exclusion criteria were selected for the study. *Inclusion criteria* :Teeth with a mild or moderate grade of fluorosis, consent for treatment and caries-free teeth. *Exclusion criteria*: Non-fluoride stains of teeth, fractured, carious, grossly decayed teeth. Written informed consent was obtained from all the parents or legal guardians, who agreed and allowed their children to undergo dental examination

and subsequent treatment. Complete dental examination of each child was carried out. Teeth were examined in a relatively humid condition and under an undirected artificial light, in order to assess the degree of fluorosis, which were classified according to Dean's fluorosis index. Only, those children with mild or moderate degree of fluorosis, who complained of objectionable aesthetics were included for the study. A split mouth study design was chosen; each subject had one of their maxillary central incisors randomly selected for micro abrasion and the contra lateral maxillary central incisor for McInnes bleaching.

### McInnes Bleaching

Teeth to be treated were cleaned and the Gingiva in the selected region was protected with petroleum jelly. Then the teeth were isolated with rubber dam. Because of the caustic nature of the bleaching solution, each patient was protected with eye glass and a body drape. The operator also wore gloves, protective eye glass and a face mask. A fresh solution of bleaching mixture was prepared for each patient in a dappen dish. The bleaching mixture consists of, 1ml, of 36%HCL, 1ml of 30% H<sub>2</sub>O<sub>2</sub>, 0.2ml of Diethyle Ether. Bleaching mixture was then applied over the area of discoloration present on the facial surface of tooth, using a cotton applicator. The solution was reapplied as often needed until an acceptable esthetic improvement was achieved or to an extent of maximum 5 minutes. To neutralize the bleaching solution, tooth was then flooded with baking soda solution and copious irrigation with water. At the end of the procedure, topical APF was applied for 4 minutes.<sup>1,4</sup>

### Enamel microabrasion

Microabrasion was performed as described by Croll and Cavanaugh. Briefly, before treatment, tooth was isolated with rubber dam, gums covered with a petroleum jelly and face by protective eye glass. The operator also wore a protective eyeglass. For each subject, fresh 18%HCL was mixed with fine pumice powder in a dappen dish to form a thick moist paste. Later, acid- pumice mixture was applied over the area of discoloration for 5 sec. using a rotating rubber cup in a slow speed hand piece with very light pressure and then rinsed for 15 sec, with a water stream and dried with compressed air. The procedure was repeated until, all stains were removed and desired correction was achieved. If no change was apparent after 12 to 15 such applications, the procedure was terminated. To avoid excessive loss of enamel after each application, enamel depth was carefully evaluated in order to prevent notable enamel loss. At the end of the procedure, topical APF was applied for 4 min.<sup>5</sup>

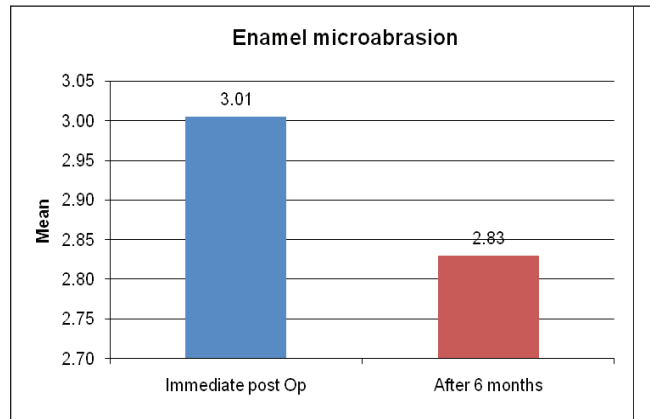
### Esthetic improvement assessment

Esthetic improvement was assessed by comparing the pre and post operative digital photographs. Photographs were taken just before the procedure, immediately after the procedure and at a six months interval. All the photographs were taken using the same background, camera(cannon 580) and similar settings(auto mode, macro and without flash}. During the evaluation session, the pre and post operative photographs of 30 subjects were incorporated into a power point presentation and were projected side by side in a darkened room assessed by four calibrated and blinded examiners, including a lay man under standardized viewing conditions. The examiners rated the improvement in esthetics for two different procedures separately, on visual analogue scale that ranges from 1-7.<sup>5</sup> The panel

**Table 1.** Comparison between the raters while rating for Enamel microabrasion.

			Rater1	Rater2	Rater3	Rater4	P* Value	Sig.
Enamel microabsion	Immediate.	Mean	3.03	3.02	3.00	2.96	P=0.99	N.s
		SD	±1.22	±1.25	±1.30	±1.20		
	6Month	Mean	2.85	2.83	2.87	2.77	P=0.98	N.S
		SD	±1.17	±1.22	±1.28	±1.11		

One way ANOVA test



**Graph 1.** Mean ratings for esthetic improvement of enamel micro abrasion at immediate and six month interval.

of judges were instructed to draw a line on visual analog scale(VAS) which best described the improvement in aesthetics. Immediate and six month aesthetic change were assessed. The immediate by comparing pre op, and immediate post op photographs where as, six month esthetic retention by comparing immediate post op with six month post op Photographs.

**Sensitivity recording**

The sensitivity was recorded for two techniques separately. Here, the tooth surface was exposed for one second for a blast of air delivered from a standard dental air syringe as per American dental association recommended guidelines.<sup>6</sup> Sensitivity was then recorded based on subject’s response using air sensitivity scale by Schiff.<sup>7</sup> Sensitivity was recorded immediately after the procedure. Any change in sensitivity was recorded at intervals of one, three and six months for each procedure.

**Sensitivity Scale**

- 0 Tooth /subject does not respond to air stimulus.
- 1 Tooth /subject responds to air stimulus but does not request discontinuation of stimulus.

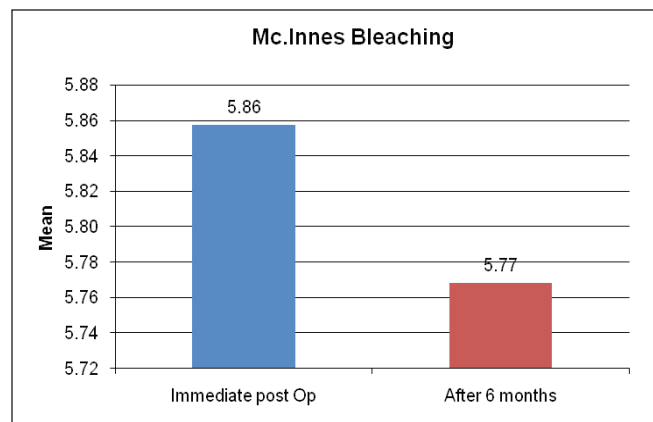
- 2 Tooth /subject responds to air stimulus. Requests discontinuation or moves from stimulus.
- 3 Tooth /subject respond to air stimulus. Considers stimulus to be painfull and requests discontinuation of stimulus.

**RESULTS**

**Table 1 and Graph 1:**

It shows the mean and standard deviations of all the four raters, for both immediate and six- month improvement for enamel microabrasion procedure. The table also shows, the p value for both immediate and six months interval. The p value for immediate is 0.99 and for six months it is 0.98. Both are not significant. This indicates that, there is a high degree of a co-relation among all the four raters while rating for, immediate and six months improvements for enamel micro abrasion procedure.

**Table 2 and Graph 2:** It shows the mean and standard deviations of all the four raters, for both immediate and six months improvement for McInnes bleaching procedure. The table also shows the p value for both immediate and six months. The p value for immediate is 0.97 and for 6 month it is 0.69. Both are not significant. This indicates that there is a high degree of co relation among all the four raters while rating immediate and six month improvements for McInnes procedure.



**Graph 2.** Mean ratings for esthetic improvement of McInnes bleaching at Immediate and six month interval.

**Table 2.** Comparison between the raters while rating for McInnes bleaching.

			Rater1	Rater2	Rater3	Rater4	P* Value	Significance
McInnes Bleaching	Immediate	Mean	5.90	5.87	5.85	5.82	P=0.97	Not significant
		SD	±0.82	±0.52	±0.68	±0.85		
	6 Months	Mean	5.79	5.83	5.65	5.80	P=0.69	Not significant
		SD	±0.59	±0.59	±0.69	±0.57		

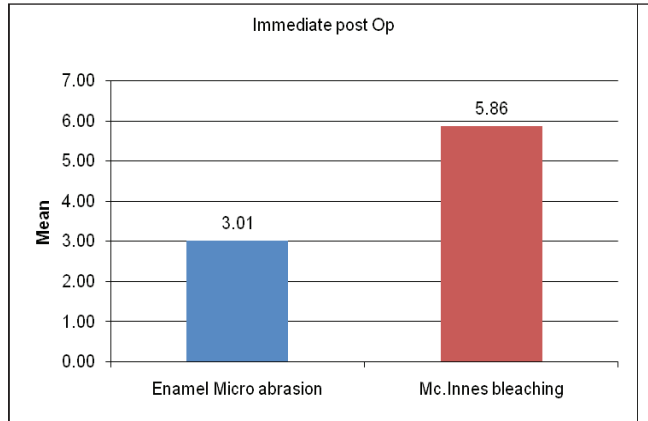
\* One way ANOVA test

# Comparison of Relative Efficacy of Two Techniques of Enamel Stain Removal on Fluorosed Teeth

**Table 3.** Comparison between the two procedures.

Procedures	Enamel microabrasion		Mc. Inne's Bleaching		Mean Difference	P* Value	Significance
	Mean	SD	Mean	SD			
Immediate post Op	3.01	±1.22	5.86	±0.65	2.85	P<0.001	Highly significant
After 6 months	2.83	±1.17	5.77	±0.54	2.94	P<0.001	Highly significant

\*Student's unpaired t test



**Graph 3.** Comparison between the two procedures at immediate post op.

**Table 3,4 and Graph 3,4:** It illustrates, the comparison between the two procedures. The mean difference between the McInnes bleaching and enamel microabrasion at immediate post op. is 2.85 and at six months interval is 2.94 respectively. This indicates that McInnes bleaching is superior to enamel microabrasion both at immediate post op and at six month intervals.

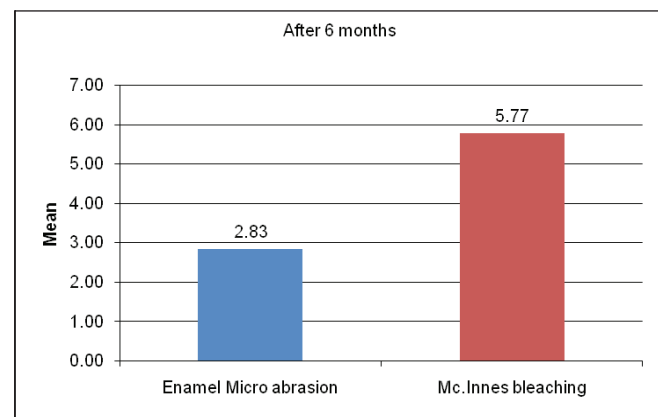
**Table 5 and Graph 5** Illustrates, mean and standard deviation for sensitivity for both the procedures. The mean sensitivity recording for enamel microabrasion was found to be 0.33 and 0.43 for McInnes bleaching. The p value is found to be 0.53 which indicates no significant difference between the two. No sensitivity was found for both the procedures at one, three and six month intervals.

## DISCUSSION

Patients, who seek treatment for an esthetically objectionable fluorosis would like to preserve the tooth structure and achieve a reasonably improved appearance of their smile. The brown stain of fluorosis is particularly distressing to the patient.<sup>8</sup> The most conservative ways to treat the dental fluorosis include enamel micro abrasion and bleaching with McInnes solution. Thus, the present clinical study was conducted to compare and evaluate, the relative efficacy of enamel micro abrasion (using 18% HCl) and bleaching with McInnes solution in the aesthetic improvement of fluorosed teeth and to check postoperative sensitivity. 30 children aged between 9-14yrs with a mild or moderate grade of fluorosis, as classified according to Dean's fluorosis index and those who complained

of objectionable esthetics were selected. Most children belonged to moderate category. Children below moderate grade of fluorosis never reported with objectionable esthetics. The study was carried out with split mouth study design. Each subject had one of their maxillary central incisors randomly selected for micro abrasion and the contra lateral for McInnes bleaching. This design of study has many advantages over the parallel study design and the cross over study design. Here, the same participant acts as the subject and control. Therefore, fewer participants are required to obtain same study power as parallel group and every participant receives both the interventions thereby providing good determining preferences. While selecting the subjects, priority was given for those subjects who had equal distribution of pre-operative enamel discoloration stains. Esthetics is a subjective perception. Some authors, who used an index with an arbitrary cut off to designate classes of defects as esthetically objectionable, may not reflect the communities nor the individual's perception of cosmetic acceptability. Esthetic values of a dentist may not reflect those of lay man.<sup>9</sup> In a study done by Limback, the esthetic improvement after microabrasion was assessed by a panel of three judges including a layman.<sup>8</sup> In another study by Price, the esthetic improvement after microabrasion with PREMA compound was done by four calibrated and blinded examiners.<sup>5</sup> So, in the present study the esthetic improvement assessment was done by four calibrated and blinded examiners including a layperson.

The esthetic improvement was assessed with the help of a VAS. The scale has a range from 1-7, with 1 indicating no improvement in esthetics and 7 indicating exceptional improvement.<sup>5</sup> All the four raters were blinded and calibrated before assessment. We



**Graph 4.** Comparison between the two procedures at sixmonth.

**Table 4.** Comparison between Immediate post op and six months later observation.

	Immediate post Op	After 6 months	Mean Difference	P* Value	Sign.
Enamel microabrasion	3.01	2.83	0.18	P<0.001	HS
Mc. Inne's Bleaching	5.86	5.77	0.09	P=0.11	NS

\*Student's paired' t' test

**Table 5.** Sensitivity analysis.

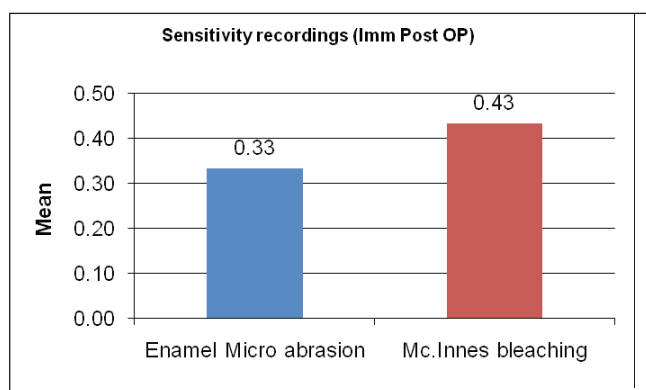
Time of assessment	Enamel microabrasion		Mc. Innes Bleaching		P* Vlaue	Sig
	Mean	SD	Mean	SD		
Immediate Post op	0.33	±0.48	0.43	±0.57	P=0.53	N.S.
1 Month	0.00	0.00	0.00	0.00	-	-
3 Month	0.00	0.00	0.00	0.00	-	-
6 Month	0.00	0.00	0.00	0.00	-	-

\* Mann Whitney U test

assessed them for intra-rater reliability and inter-rater reliability having them unknowingly rate 5 duplicate slides of the same treatment. All the raters correctly identified that, there were no differences in these paired identical slides. We also tested the intra-rater reliability, by asking the evaluators to rate five pairs of pre and post-operative images twice. The intra-class correlation between the raters for both the procedures was calculated and it was found that for enamel microabrasion it was 0.9 and for McInnes bleaching 0.7. These values indicate that there was a good level of a co-relation among the raters while rating for both the procedures. The intra-examiner reliability was also calculated for both the procedures and was also found to be insignificant. In the present study, the aesthetic improvement was assessed for both enamel microabrasion and McInnes bleaching immediately after the procedure and at a six months interval. The mean value for instant esthetic improvement for enamel microabrasion was found to be 3.01 and for McInnes bleaching its 5.86. This clearly indicates that, immediate esthetic improvement by McInnes bleaching is far superior compared to enamel microabrasion. In a study done by Price, the mean improvement in esthetics for enamel microabrasion was found to be 5.38.<sup>5</sup>

The results as judged by both the expert observers and a lay man showed that, there was a significant improvement in esthetics of teeth after McInnes bleaching but not with enamel microabrasion. This is in contrast with some of the studies, which have noted that the enamel microabrasion is a very effective procedure in treating superficial enamel stains. This could be due to some of the unresolved issues regarding enamel microabrasion. There is a lack of clear guidelines about which grade of fluorosis be treated by enamel microabrasion. Some authors indicate that, enamel stains can often be removed when confined to superficial enamel layers and advocate that, enamel microabrasion technique be considered as first choice. However, it is hard to ascertain clinically, which stain is superficial enough to be treated by enamel microabrasion. Croll, has stated that it is difficult to determine which enamel stains is sufficiently superficial for microabrasion correction, but most brown stains are superficial enough for removal.<sup>10</sup>

Treatment duration of microabrasion is still not established. Some authors report that, microabrasion be abandoned after a fifteen 5 second applications. Others suggest that, a typical session consists of only five microabrasion treatments but provides no time for treatment.<sup>11</sup> So in our study a fifteen, 5 second application was considered to be a maximum limit. Ashkenazi and Sarnat also concluded that, additional clinical studies should be performed in order to establish guidelines for microabrasion. The guidelines should include, selection of patient, type and severity of enamel developmental disorders, optimal age for treatment, time, number of appointment for safety treatment, and long term effects.<sup>12</sup> The exact mechanism by which



**Graph 5.** Comparison of Sensitivity at immediate post op.

microabrasion eliminates discoloration and improves appearance of dysmineralized enamel is not completely understood. However, it may be that during micro abrasion the acids dissolve the residual organic material (including pigmentation) and loosely mineralized tissue. After the dissolution, fluoride and salivary minerals enable correct "impact remineralization."of enamel. Another possible explanation to the success of treating hypo matured enamel is the fact that, newly micro abraded surface reflects and refracts the light in such a way that mild imperfections in the underlying enamel are blurred. Most of the reports of the literature on HCL pumice method have been case reports, and and the procedure may be a technique sensitive. Quantification of the effectiveness of this treatment has only recently been done. A study conducted by Train et al compared the effectiveness of microabrasion procedure with PREMA micro abrasion kit in mild to moderate and severe fluorosis enamel stains. The authors found that mildly stained teeth achieved better esthetic results, moderately stained teeth improved, but continued to demonstrate white spots and staining and severely stained teeth showed only slight improvement<sup>3</sup>. This is almost similar with our finding, where the study also noticed that enamel microabrasion is not effective in removing stains of even moderate grade of fluorosis. In a study done by Ashkenazi *et al*, the results of micro abrasion in all the five treated patients were surprising and gratifying. At the end of micro abrasion, the enamel developed a glass like surface which caused teeth to have healthier optical properties even after 4 yrs and no discomfort was observed.<sup>12</sup>

The instant esthetic improvement with McInnes bleaching in our study was significant with a mean improvement of 5.86. All the four raters, including lay man found that there was moderate to exceptional improvement in esthetics. McInnes solution contains, Five parts of 30% H<sub>2</sub>O<sub>2</sub> (1ml), five parts of 36% HCL (1ml), one part of ether (0.2ml). The HCL etches the enamel and removes some

of the stains; H<sub>2</sub>O<sub>2</sub> bleaches the enamel, and ether is a solvent to take away surface contaminants from the enamel enabling the penetration of H<sub>2</sub>O<sub>2</sub>.<sup>4</sup> The reason for better efficacy of enamel micro abrasion in removing stains could be attributed to a difference in concentration of HCL used. It is almost double than used in microabrasion. Mc Innes's solution has three different chemicals, which have an additive effect for stain removal. A Study was done by Colon, who treated 400 patients with fluorosis using McInnes technique. He concluded that, McInnes technique of bleaching improves the appearance of individual while preserving tooth structure.<sup>1</sup>

The six month ratings for enamel microabrasion and McInnes bleaching as assessed by four raters were 2.83 and 5.77 respectively. These ratings were less, compared to the mean ratings of immediate assessment, which were, 3.01 and 5.86. However, the reduction in these ratings is statistically significant for enamel micro abrasion and insignificant for McInnes bleaching. This indicates that, there was reduction in esthetic improvement in both the procedures at a six month interval, but it is comparatively more in enamel microabrasion. The results are contradictory to Croll's findings, who noted additional improvement in esthetics after six month following micro abrasion. This may be because the enamel surface undergoes remineralization and attains a super smooth glass like surface. In another study Croll, evaluated the long term results of enamel microabrasion using 18% HCL and pumice. It was found that after six month of treatment, in most cases additional improvement in colour was seen namely, treated enamel surface appeared smoother, lustrous and brighter at six month. The study also concluded that HCL pumice abrasion method of enamel colour modification be considered as first treatment of choice in patients with enamel colouration defect.<sup>8</sup> A clinical followup study of 2.5-4 yrs was done to determine, the esthetic benefit of microabrasion in five children with moderate enamel dysmineralization resembling two different types of hypo maturation amelogenesis imperfect, Snow capped and pigmented autosomal recessive subtypes. Two families with different types of discolouration were treated, one with white and other with brown discoloration. The study found that, in all the patients staining did not reoccur. Tooth looked healthier and harder.<sup>12</sup>

In the present study, the sensitivity after both the procedures were recorded immediately, at one month, three month and six month interval. It was observed in the study that, 10 subjects had mild immediate sensitivity after McInnes bleaching and 12 subjects after enamel microabrasion. Further recording of sensitivity at one, three and six months were unyielding since, none of the subjects showed sensitivity for both the procedures. These results indicate that, sensitivity after these two conservative esthetic procedures is transient and there is no significant difference between the two procedures.

There have been no long term studies to examine the safety of peroxide on oral tissues, especially with the pulp.<sup>13</sup> In this study we have attempted to measure the severity of dentinal sensitivity and its accompanying effects on pulp over a period of time. The study has proven the fact that the dentinal sensitivity after bleaching and enamel microabrasion is transient and will subside within a month. A study by Croll compared the effectiveness of microabrasion with PREMA compound versus high speed 12 fluted bur with water spray in removing incisor hypomineralized defects. It was found that both techniques were effective in removing the brown hypomineralized enamel defects, and none of the cases reported of post operative sensitivity.<sup>14</sup>

There have been no studies to determine, if HCL in new low acid formula can penetrate enamel completely and jeopardize the odontoblastic tubules. However, in 1977 Griffen and co-workers tested radioisotope Ph-32 labeled 30% H<sub>2</sub>O<sub>2</sub>, 36% HCL, isotonic saline and a mixture of H<sub>2</sub>O<sub>2</sub>, HCL and diethyl ether and concluded that, none of the solutions penetrate the enamel to reach DEJ. They revealed that neither HCL nor H<sub>2</sub>O<sub>2</sub>, HCL, Diethyl ether combination, increase enamel dentin permeability in extracted teeth.<sup>15</sup> Baumgartner showed that, applying a mixture of 36% HCL, 30%, H<sub>2</sub>O<sub>2</sub>, diethyl ether to human premolars has no pulpal effects. Creig *et al*, in a study reported that the histological evaluation of pulp revealed little or no reaction on pulp even after extensive bleaching regimens of 15 min. Stanley and co workers also agreed that there is increased dentin permeability when acids were used on dentin and co related degree of pulpal response to remaining dentin thickness. Crieg *et al* has also stated that only some enamel was lost following the first five minute application of McInnes solution and 15 second disking. Following three such application considerable enamel loss occurred. So they have warned that even though 15 min. application of bleaching mixture may not cause marked pulpal reaction, it can remove significant tooth structure, which may affect the long term prognosis of pulp.<sup>3</sup> Colon reported that none of the patients treated by him complained of pain during or after treatment. Six patients experienced slight increase in sensitivity to cold that disappeared within 48 hours indicating transient hyperemia. Possibilities of permanent pulpal damage or cracks to enamel due to use of heat or strong light are reduced since neither heat nor light is used. He concluded from his studies that Mc Innes bleaching is safe, practical and time consuming.<sup>1</sup> Histologic studies regarding the effect of acid penetration through enamel into the pulp show that penetration has been insignificant. Waggoner *et al* studied nine extracted molars after they were subjected to Croll and Cavanaugh 18% HCL pumice mixtures for 10 sequential 5 second application. They concluded that 25% of the labial enamel was removed. They also reported the amount of enamel removal with various acid pumice mixture. The rates of enamel loss per 5 second application ranged from enamel loss of 200µm from enamel micro abrasion.<sup>16</sup>

This study was not the first study to quantitatively measure the improvement in esthetics of fluorosed teeth after microabrasion. Most reports of the literature are individual case reports, and few studies have also measured the esthetic improvement after microabrasion. But none of the studies have compared the two well known techniques of treating fluorosed teeth *in vivo*. This study has made an attempt to compare both the procedures using split mouth study design and to record the long term effects of both the techniques.

### CONCLUSION

1. Both Immediate and six month esthetic change achieved by McInnes bleaching were superior to enamel micro abrasion.
2. There was a reduction in esthetic appearance of the teeth in both the procedures after six months but this is comparatively less in McInnes bleaching.
3. Postoperative sensitivity was negligible after both techniques.
4. The sensitivity observed after both the techniques were transient and subsided within one month post operatively. None

of the subjects reported sensitivity at one, three and six month intervals.

5. Thus, the study concludes that McInnes bleaching is more effective than enamel micro abrasion and both the procedures are conservative and safe.

## REFERENCES

1. Colon PG Jr . Improving the appearance of severely flurosed teeth. *J Am Dent Assoc.* 86(6) :1329-31. 1973.
2. Beiley RW, Christen AG. Effect of a bleaching technique on the labial enamel of human teeth stained with endemic dental fluorosis. *J Dent Res;* 49(1):168-170. 1970.
3. Train TE, McWhorter AG, Seale NS, Wilson CF, Guo IY. Examination of esthetic improvement and surface alteration following microabrasion in fluorotic human incisors in vivo. ;18(5):353-62. 1996
4. Grossman LI, Seymour O, Carlos ED, Endodontic Practice, Philadelphia, Lea & farbigier, 11th ed. 276-271. 1991.
5. Price RB, Loney RW, Doyle MG, Moulding MB. An evaluation of a technique to remove stains from teeth using micro abrasion ; *J.Am.Dent Assoc.* Aug;134(8):1066-71. 2003.
6. Giniger M, Macdonald J, Ziemba S, Felix H. The clinical performance of professionally dispensed bleaching gel with added amorphous calcium phosphate. *J Am Dent Assoc.; Mar;*136(3):383-92. 2005.
7. Sowinski J, Ayad F, Petrone M, DeVizio W, Volpe A, Ellwood R, Davies R. comparative investigation of the desensitizing efficacy of new dentifrice. *J.Clin.Periodontol.;* 28(11):1032-36. 2001.
8. Limeback H, Vieira AP, Lawrence H. Improving esthetically objectionable human enamel fluorosis with a simple microabrasion technique. *Eur J Oral Sci.May;*114 Suppl 1:123-6; discussion 127-9, 380. 2006.
9. Wong FS, Winter GB. Effectiveness of microabrasion technique for improvement of dental aesthetics. *Br Dent J.*10;193(3):155-8. 2002.
10. Croll TP, Cavanaugh RR. Enamel color modification by controlled hydrochloric acid-pumice abrasion. I. Technique and examples. *Quintessence Int.*Feb;17(2):81-7. 1986.
11. Donly KJ, Donly AS, Baharloo L, Rojas-Candelas E, Garcia-Godoy F, Zhou X, Gerlach RW. Tooth whitening in children. *Compend Contin Educ Dent.* Jan;23(1A):22-8; quiz 49. 2002.
12. Ashkenazi M, Sarnat H. Microabrasion of teeth with discoloration resembling hypomaturation enamel defects: four-year follow up. *J Clin Pediatr Dent.* 25(1):29-34. 2000
13. Baumgartner JC, Reid DE, Pickett AB. Human pulpal reaction to the modified McInnes bleaching technique. *J Endod.* Dec;9(12):527-9. 1983.
14. Coll JA, Jackson P, Strassler HE. Comparison of enamel microabrasion techniques: Prema Compound versus 12-fluted finishing bur. *J Esthet Dent.* SepOct;3(5):180-6. 1991.
15. Creig PA, Effects of solutions used to treat dental fluorosis on permeability of teeth. *J Endod.;*3(4):139-43. 1977.
16. Croll TP; Enamel microabrasion: The technique. *Quintessence Int.*20(6).395-400. 1989.

Downloaded from [http://meridian.allenpress.com/jcpd/article-pdf/38/3/207/1751101/jcpd\\_38\\_3\\_0h120kh8852p568.pdf](http://meridian.allenpress.com/jcpd/article-pdf/38/3/207/1751101/jcpd_38_3_0h120kh8852p568.pdf) by Bharati Vidyapeeth Dental College & Hospital user on 25 June 2022