

The Effect of DynaCleft® on Cleft Width in Unilateral Cleft Lip and Palate Patients

LaQuia Vinson*

Objective: The specific aim of this retrospective cross-sectional study was to assess the efficacy of DynaCleft® as a method of presurgical orthopedics with infants with a unilateral cleft lip and cleft palate who used an oral obturator. **Study design:** Data was collected from 25 infants all of comparable age diagnosed with a unilateral complete cleft lip and palate. Eight patients used DynaCleft® and an obturator (Group Alpha) and seventeen patients only had an obturator (Group Beta). Maxillary impression casts were obtained from each patient at the initial clinic visit and at the time of cleft lip repair. Differences in alveolar cleft width were compared between the two groups. Casts were measured twice by one observer using a digital caliper.

Results: Group Alpha began treatment on an average age of 24.25 days and Group Beta an average of 15.35 days of age. The average cleft width of Group Alpha was 8.13 mm and after treatment it was 4.59 mm. The average cleft width of Group Beta was 8.09 mm and 6.92 mm after treatment. Results of paired t-tests and two-sample t-test showed that cleft width changes between the two groups were significant ($P = .03$).

Conclusions: DynaCleft® significantly decreased the size of the alveolar cleft width compared to infants who did not use it. Providers should consider using DynaCleft® for patients who may not have access to infant maxillary orthopedics.

Key words: presurgical orthopedics, cleft lip and palate

INTRODUCTION

Presurgical infant orthopedics can be defined as a type of therapy that “uses forces to reposition tissues secondarily displaced due to a cleft deformity”¹. Orthopedic appliances were developed to aid in the correction of cleft lip and palate by utilizing both compression and tension forces or passively guiding growth. Several authors have reported that presurgical orthopedics have resulted in several additional benefits to patients with cleft lip and palate such as: a reduction in cleft width by stimulation of palatal shelf growth, improved maxillary arch development, improved growth of the face and infant overall, improved occlusion, feeding, speech, hearing, and language development². Other reasons given for the use of presurgical orthopedics include proper growth and development of the oral cavity, including proper posture for the resting musculature including that of the tongue³. Ultimately, the molding that occurs with presurgical orthopedic use can result in a more uniform osseous base⁴.

LaQuia A. Vinson, DDS, MPH. Assistant professor and assistant graduate program director of the post-graduate program in pediatric dentistry, in the School of Dentistry, Indiana University and pediatric dentist for the Craniofacial Anomalies Team at James Whitcomb Riley Hospital for Children, Indianapolis, Indiana.

Send all correspondence to:
LaQuia A Vinson:
705 Riley Hospital Dr., Suite 4205
Indianapolis, IN 46202
Phone: 317-948-0886
E-mail: laqawalk@iu.edu

There are many methods of presurgical orthopedics for patients with cleft lip and palate. Nasoalveolar molding also known as NAM therapy orthotopically repositions both the alveolar segments and nasal cartilages prior to cleft lip repair⁵. The effect of this type of presurgical orthopedics is that a less extensive surgery is required for the lip and nasal repair and there is less tension on the reconstruction, theoretically resulting more predictable reconstructive results. Indeed, greater nasal symmetry is obtained after cleft lip repair using NAM therapy and NAM has been demonstrated to be a cost effective means of cleft lip repair when patients are followed long term⁶⁻⁷.

Although NAM therapy is considered one of the most effective forms of presurgical orthopedics, it is also one of the most time consuming procedures available to patients. NAM is a labor intensive technique that requires the construction of custom made alveolar splints and nasal molding devices by the dental team. NAM therapy requires frequent visits, traditionally weekly, from the time of initial appliance placement until the time of lip repair surgery. This can increase the number of office visits by 8 in unilateral cleft lip and palate patients. Lip adhesion surgery has been another method used in patients born with wide clefts, but it has been criticized for its additional risk and expense to patients as well as its high rate of dehiscence and scarring⁸.

DynaCleft® is a premade topical approximation device which has been successfully used to mold the upper lip and alveolus, and support the developing nasal tissues prior to cleft lip repair (Figure 1). While traditional surgical adhesive tape (e.g. Silk tape,

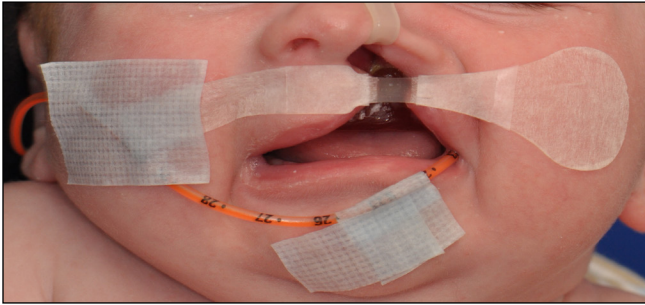Figure 1. Patient with DynaCleft® in place

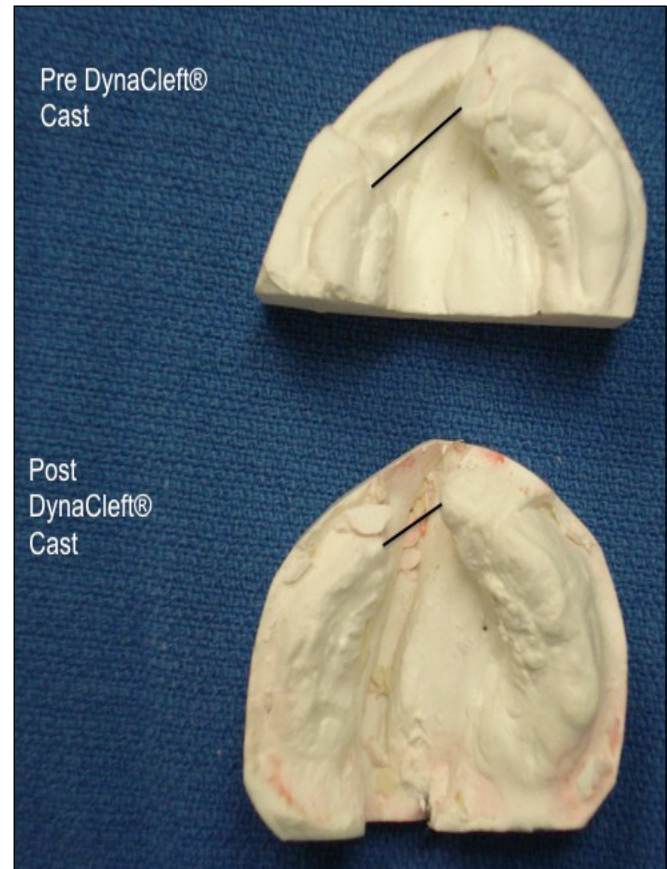
Image courtesy of Riley Hospital for Children Craniofacial Anomalies Center

Steri-strips®) have been used in the past, unlike tape, DynaCleft® offers the benefit of being able to provide a constant approximation force with an elastic center that allows it to conform to a baby's mouth better because of its ability to expand and contract⁹. Additionally, the controlled force that it provides to the prolabium and premaxilla could improve cheiloplasty surgical results and decrease the necessity of early lip adhesion surgery. As the DynaCleft® device is premade, there is no need to create custom-made devices for the molding process. Therefore, there is no labor cost associated with DynaCleft® therapy unlike NAM therapy. Additionally, current research has demonstrated that adequate molding of the lip, alveolus, and nose can be accomplished using DynaCleft® through less frequent visits than required by NAM which decreases the burden on families undergoing presurgical orthopedic treatment¹⁰. Nonetheless, one of the greatest benefits of using DynaCleft® in presurgical orthopedic therapy is the ability for families to minimize clinical visits since no professional adjustment is needed to use it. It also has the ability to be used in conjunction with intraoral plates^{9, 11}. Parents are given both written and hands-on instruction on how to place DynaCleft® as well as how often to replace it. The specific aim of this study was to assess the effect of DynaCleft® as a method of presurgical orthopedics in infants born with a unilateral cleft lip and cleft palate in reducing their alveolar cleft width.

MATERIALS AND METHOD

This retrospective study was conducted at an urban children's hospital that serves children of a variety of ethnic backgrounds and was approved by the Institutional Review Board as Study #1111007344. Data was collected from 25 infants diagnosed with a unilateral complete cleft lip and palate over a three year period. All patients had maxillary alginate impressions for obturator fabrication obtained at their initial visit to the craniofacial center and immediately before cleft lip repair surgery. The impressions were immediately poured in dental stone. Group Alpha was provided DynaCleft® (Southmedic, Ontario, Canada) at their initial clinic visit and the parents received one-to-one and written instruction on its placement (Figure 1). Group Beta was composed of patients who had not received DynaCleft® because they were patients of the center prior to its institution of the use of DynaCleft®. The infants were all of comparable age, and were less than one month old at the time of their first visit.

The dental casts that were created for the obturator fabrication were indirectly measured. Manual measurement of cast study models with a caliper is considered the gold standard¹². A coordinate

Figure 2. Pre and Post DynaCleft® casts

system was utilized using conventional landmarks denoted on the casts: right tuberosity (RT) and left tuberosity (LT) points, right canine (RC) and left canine (LC) points, the incisal (I) point, right alveolar crest (RA) end point and left alveolar crest (LA) to standardize the points of measurement¹³. Each dental cast for the initial and follow up dates was measured twice by one observer with a Carrera Precision digital caliper (Max Tool LLC, LaVerne CA), and the results averaged and recorded into an electronic spreadsheet. The intersegment distance was measured as the distance between the right and left tuberosity points, and the intercanine distance was measured as the distance between the right and left canine points. The intercleft distance or cleft width was measured as the distance between the right and left alveolar crests. Differences in alveolar cleft width were compared within and between the two treatment groups. Alveolar cleft distance was summarized and paired t-tests were used to test for significant changes between the pre-treatment and post-treatment measurements for each group. Two-sample t-tests were used to compare the changes between groups.

RESULTS

Group Alpha began treatment on an average age of 24.25 days and Group Beta an average of 15.35 days of age. The average time between impressions for Group Alpha was 114 days and for Group Beta 108 days. The average cleft width of Group Alpha (the DynaCleft® group) was 8.13 mm and after treatment it was 4.59 mm. The average cleft width of Group Beta was 8.09 mm and 6.92 mm after treatment. Patients who had received DynaCleft® saw an average decrease in cleft width of 3.5 mm while those who had not received

DynaCleft® saw an average decrease in cleft width of 1.17mm (Figure 3). The average intertuberosity and intercanine distances are listed in (Figure 4) which showed no significant changes in arch dimensions. Results of paired t-tests and two-sample t-test showed that cleft width changes between the two groups were significant ($P = 0.03$).

Figure 3. Changes in alveolar cleft width

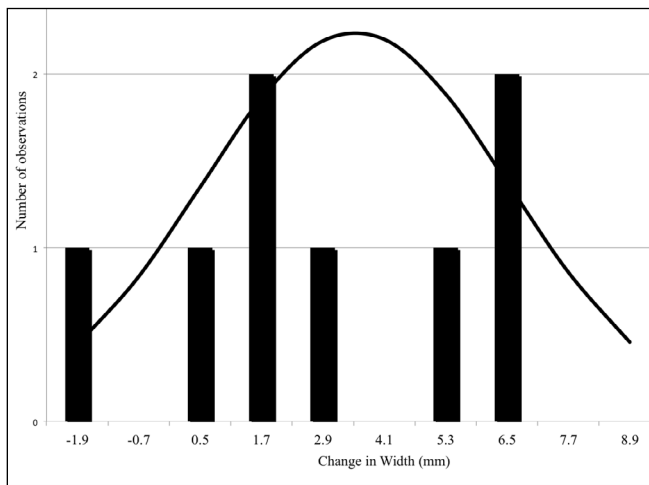
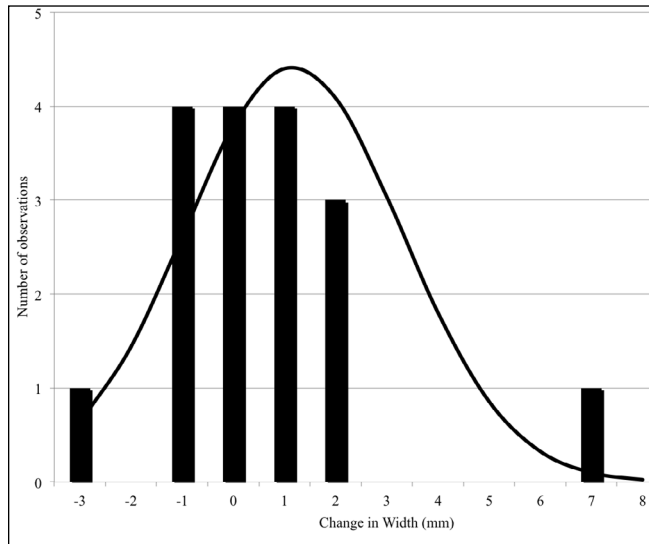


Figure 4. Changes in inter-tuberosity and inter-canine distance

Group Alpha	Inter-tuberosity width (mm)	Inter-canine width (mm)
Initial	33.74	29.06
Pre-operative	34.48	29.59
Difference	0.74	0.52
Group Beta		
Initial	34.51	32.22
Pre-operative	35.12	33.36
Difference	0.62	1.14
p Group Comparison	0.90	0.62

DISCUSSION

This study was the first of its kind that assessed the effect of DynaCleft® as a method of preoperatively reducing cleft width for infants with cleft lip and palate. While this study did show that DynaCleft® was effective in reducing cleft width in those patients who used it, the elastomeric properties of DynaCleft® is the likely reason there was a decrease in cleft width. There were limitations of this study including the limited number of infants who were treated with DynaCleft® as well as the possibility of variability in following the treatment protocol for DynaCleft® by caregivers of the patients.

The primary goal of management of the cleft deformity is achieving normal anatomy and function with presurgical orthopedics serving as an adjunct for surgeons to accomplish this.¹⁴ However, presurgical orthopedics still remains a controversial subject even though it has been the established practice of many craniofacial teams worldwide and has historically aided in reducing the size of the alveolar cleft prior to surgery.¹⁵ Yet, as it was noted by Adali and colleagues, “the effect of presurgical orthopedics are manifested most clearly before the effects of lip repair”, and, according to Prahl *et al* the effects do not last beyond surgical soft palate closure.^{2,16} Nonetheless, advantages such as facilitation of feeding, normalization of tongue function, reduced risk of aspiration, improvement of speech and archform provide justification for their continued use to many providers.^{14, 17}

In spite of the controversy that exists regarding the use of presurgical orthopedics in cleft lip and palate care, pediatric dentists will continue to play a vitally critical role in their use by fabricating them for nearly 35% of all craniofacial teams in the United States.¹⁸ Even though surgical lip closure has a greater effect on decreasing cleft width than presurgical orthopedics and the NAM procedure is still very widely used, those practitioners who still desire a method to reduce cleft width who do not have the resources to utilize NAM therapy do have a viable option with DynaCleft®¹⁹.

CONCLUSION

The results of this study showed that using DynaCleft® as a method of presurgical orthopedics is an effective method of reducing cleft width. DynaCleft® significantly decreased the size of the alveolar cleft width of patients with unilateral complete cleft lip and palate compared to infants who did not undergo DynaCleft® therapy. Nonetheless, this technique may provide teams who do not have access to more traditional methods of presurgical orthopedics an effective alternative to use for treating these infants.

ACKNOWLEDGEMENTS

I would like to thank Mr. George Eckert and Mr. Marvin Thomas for their assistance with this study. This study was supported by the Women for Riley.

REFERENCES

1. Jaeger M, Braga-Silva J, Gehlen D, Sato Y, Zuker R, Fisher D. Correction of the Alveolar Gap and Nostril Deformity by Presurgical Passive Orthodontia in the Unilateral Cleft Lip. *Ann Plastic Surg* 59:489-494, 2007.
2. Adali N, Mars M, Noar J, Sommerlad B. Presurgical orthopedics has no effect on archform in unilateral cleft lip and palate. *Cleft Palate Craniofac J* 49:5-13, 2012.
3. Kozelj V. The basis for presurgical orthopedic treatment of infants with unilateral complete cleft lip and palate. *Cleft Palate Craniofac J* 37:26-32, 2000.
4. Marsh H, Vannier MW. *Comprehensive Care for Craniofacial Anomalies*. St. Louis, CV Mosby 1985.
5. Grayson, BH, Santiago PE, Brecht LE, Cutting CB. Presurgical nasoalveolar molding in infants with cleft lip and palate. *Cleft Palate Craniofac J* 36:486-98, 1999.
6. Barillas I, Dec W, Warren SM, Cutting CB, Grayson BH. Nasoalveolar molding improves long-term nasal symmetry in complete unilateral cleft lip-cleft palate patients. *Plast Reconstr Surg* 123:1002-6, 2009.
7. Pfeifer TM, Grayson BH, Cutting CB. Nasoalveolar molding and gingivoperiosteoplasty versus alveolar bone graft: an outcome analysis of costs in the treatment of unilateral cleft alveolus. *Cleft Palate Craniofac J* 39:26-9, 2002.
8. Pool R, Farnworth TK. Preoperative lip taping in the cleft lip. *Ann Plast Surg* 32:243-249, 1994.
9. <http://www.webcitation.org/query?url=http%3A%2F%2Fsouthmedic.com%2Fproducts%2FdynaCleft-cleft-lip-approximation%2F&date=2015-11-06>
10. Monasterio L, Ford A, Guitierrez C, Tastets ME, Garcia J. Comparative study of nasoalveolar molding methods: nasal elevator plus DynaCleft® versus NAM-Grayson in patients with complete unilateral cleft lip and palate. *Cleft Palate Craniofac J* 50:548-54, 2013.
11. Grayson BH, Cutting CB. Presurgical nasoalveolar orthopedic molding in primary correction of the nose, lip, and alveolus of infants born with unilateral and bilateral clefts. *Cleft Palate Craniofac J* 38:193-8, 2001.
12. Lewis BR, Stern MR, Willmot DR. *Cleft Palate Craniofac J*. Nov;45(6):639-46, 2008.
13. Peltomäki T, Vendittelli BL, Grayson BH, Cutting CB, Brecht LE. Associations between severity of clefting and maxillary growth in patients with unilateral cleft lip and palate treated with infant orthopedics. *Cleft Palate Craniofac J* 38:582-6, 2001.
14. Radhakrishnan V, Sabarinath VP, Thombare P, Hazarey PV, Bonde R, Sheorain A. Presurgical nasoalveolar molding assisted primary reconstruction in complete unilateral cleft lip palate infants *J Clin Pediatr Dent*. Spring;34(3):267-74, 2010.
15. Kamble VD, Parkhedkar RD, Sarin SP, Patil PG Presurgical nasoalveolar molding (PNAM) for a unilateral cleft lip and palate: a clinical report *J Prosthodont* Jan;22(1):74-80, 2013.
16. Prah C, Kuijpers-Jagtman AM, van't Hof MA, Prah-Andersen B. A randomized prospective clinical trial into the effect of infant orthopaedics on maxillary arch dimensions in unilateral cleft lip and palate (Dutchcleft). *Cleft Palate Craniofac J* 40:337-342, 2003.
17. Niranjane PP, Kamble RH, Diagavane SP, Shrivastav SS, Batra P, Vasudevan SD, Patil P Current status of presurgical infant orthopaedic treatment for cleft lip and palate patients: A critical review. *Indian J Plast Surg*. Sep-Dec;47(3):293-302, 2014.
18. Raju R, Tate AR, The Role of Pediatric Dentistry in Multidisciplinary Cleft Palate Teams at Advanced Pediatric Dental Residency Programs *Pediatr Dent* 31:188-92, 2009.
19. Prah C, Kuijpers-Jagtman AM, van't Hof MA, Prah-Andersen B. A randomized prospective clinical trial into the effect of infant orthopaedics on maxillary arch dimensions in unilateral cleft lip and palate (Dutchcleft). *Eur J Oral Sci* 109:297-305, 2001.