

# Comparative Analysis of Space Maintenance Using Transpalatal Arch and Nance Button

Andrea Martín-Vacas\* / Antonia M. Caleyá\*\* / Nuria E. Gallardo \*\*\*

The **aim** of this manuscript analyses the efficacy of Transpalatal Arch (TPA) and Nance Button (NB) in maintaining space after the premature loss of upper primary molars. **Study design:** 54 subjects who needed space maintenance in the upper arch (23 in the TPA group and 31 in the NB group) and had radiographic follow-up until the appliance removal were enrolled in the study. The space loss was obtained from measurements carried out in initial and final radiographs. Type of dental loss and changes in molar relationship were also recorded. **Results:** The mean of space loss in the TPA group was 1.336mm, while in the NB group was 0.695mm, with no statistically significant differences between the total space loss neither the type of dental loss within the NB or TPA group ( $p > 0.05$ ). **Conclusions:** The loss of space in the unilateral second primary molar is higher in the TPA group than in the NB group, with significant statistically differences ( $p < 0.05$ ). It is concluded that the loss of the leeway space using a TPA as a space maintainer is greater than using a NB.

**Keywords:** space maintainers, space loss, pediatric dentistry, transpalatal arch, Nance button

## INTRODUCTION

Primary dentition plays an important role in the development of definitive occlusion, being a guide in the eruption of the permanent dentition. Hutchinson<sup>1</sup> and Davenport<sup>2</sup> already investigated the effects of premature dental loss in the late 19th century.

The most frequent cause of premature loss of primary teeth is dental caries<sup>3-6</sup>, which can lead to a reduction in the total arch length and secondary to it, alterations in the development of dental occlusion. The decrease in the available space for the eruption of the permanent teeth predisposes to mesial displacement during the eruption of the posterior teeth and, therefore, crowding, inclinations, rotations, ectopic eruptions, retentions and impactions of teeth, development of crossbite and midline deviations<sup>7-9</sup>. Therefore, when a primary tooth is prematurely lost, it is of great importance that a dentist carries out a complete clinical study, including radiographic records and study models, which allows individual analysis of the available space and the need or not to keep it<sup>5,6,10</sup>.

The Nance Button (NB) and the Transpalatal Arch (TPA) are bilateral superior fixed appliances whose efficacy as an anchorage device in corrective fixed orthodontics has been extensively studied<sup>11-13</sup>; however, there is little research analysing their effectiveness as space maintainers. In our clinical practice, we have observed changes in the position of the permanent molars, such as rotations or mesialization, in the follow-up over the years of patients with a TPA as a space maintainer. The differences in the design of the TPA and NB could lead to differences in the efficacy in maintaining space between them, however, there is no scientific evidence for the choice of the most suitable maintainer. The aim of the present study was to analyse and compare the efficacy of TPA and NB in maintaining space after the premature loss of upper primary molars.

\*Andrea Martín-Vacas, DDS, PhD. Postgraduate in Pediatric Dentistry. Complutense University of Madrid, Faculty of Dentistry, Master in Pediatric Dentistry, Spain.

\*\*Antonia M. Caleyá, DDS, PhD. Adjunct Professor. Complutense University of Madrid, Faculty of Dentistry, Department of Dental Clinical Specialties. Spain.

\*\*\*Nuria E. Gallardo, DDS, PhD. Associate Professor. Complutense University of Madrid, Faculty of Dentistry, Department of Dental Clinical Specialties, Spain.

Send correspondence to:

Nuria E. Gallardo

Departamento de Especialidades Clínicas Odontológicas.

Facultad de Odontología. Universidad Complutense de Madrid.

Pza. Ramón y Cajal s/n. 28040 Madrid. Spain.

PHONE: + 34 915335362

E-mail: negallar@ucm.es

**MATERIALS AND METHOD**

For the purpose of obtaining the sample selection, 559 Medical Histories of patients treated between 2007 and 2013 were analysed in the Master in Pediatric Dentistry at the Complutense University of Madrid (UCM). The inclusion criteria for being included in this cohort study were patients who had worn a NB (NB group) or a TPA (TPA group) as a space maintainer, who had a complete medical history and a radiographic follow-up. The study samples were the lateral sectors which required space maintenance after extraction of one or both primary molars in the upper arch and had a radiographic follow-up carried out with parallelized bitewing radiographs, without overlapping the interproximal contact points. Patients who had not a complete medical history, a radiographic follow-up or whose radiographs were not parallelized were excluded. Finally, the study sample was composed of 54 subjects, in which 23 measurements were carried out in the TPA group and 31 in the NB group (Figure 1). All the measurements were realized by the same operator, unknowing the appliance used in the samples to maintain the double-blind character of the study.

In order to evaluate the effectiveness of the space maintainers, an initial bitewing radiograph (I-Xr) was selected prior to tooth extraction, and a final one (F-Xr) performed on the date the space maintainer was removed. I-Xr and F-Xr measurements were made from mesial of the permanent molar to distal of the primary canine, obtaining the variable space loss (SL) from the difference between these measurements. To correct the possible effect of size distortion between the initial and final radiographs, a ratio factor between I-Xr and F-Xr was applied, calculating the mesio distal measurement of the same tooth on both radiographs.

The type of dental loss was recorded, classifying the cases into seven groups according to the absent molar o molars: unilateral

first molar, bilateral first molar, unilateral second molar, bilateral second molar, contralateral first and second molar, unilateral first and second molar and more than two molars loss.

Changes in the molar relationship were evaluated by comparing the records of the initial and final relationship, and were recorded as: absence of changes, mesialization of the upper arch (e.g. change from Angle molar class I to class II) and distalization of the upper arch (e.g. change from Angle molar class I to class III).

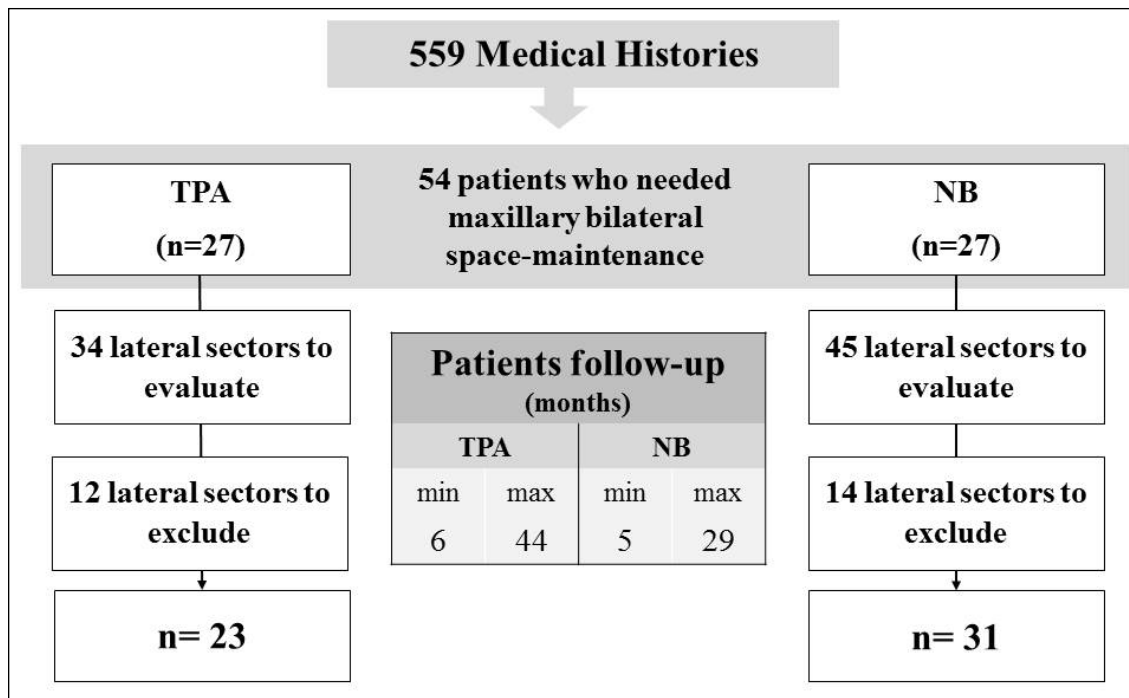
The data obtained were analysed using the IBM SPSS Statistics 24® software. In order to evaluate the consistency of the SL measurements, the intra-class correlation coefficient (ICC) was calculated repeating the measurements in ten random samples. Due to the small size, we decided to carry out both parametric and non-parametric tests for inferential analysis of the results. SL was compared between the study groups, and different subgroups, using the Student’s t-test, Mann-Whitney test and Kruskal-Wallis test. Furthermore, changes in the molar relationship were evaluated using Fisher’s exact test. A 95% confidence level (p<0.05) and asymptotic significance were used in all statistical tests, except for the Fisher’s exact test, performed with exact significance.

**RESULTS**

**Evaluation of space loss**

Finally, 23 measures of the TPA group and 31 of the NB group were obtained, with a follow-up between five and 44 months (Figure 1). The ICC obtained from I-Xr (1.00) and F-Xr (0.999) showed an excellent agreement in the measurements. The mean of space loss in the TPA group was 1.336mm, while in the NB group was 0.695mm, the data of both groups follows a normal distribution (Table 1 and Figure 2). The results of both parametric (p T-test = 0.211) and non-parametric (p Mann-Whitney = 0.154) tests indicate that there are no significant differences in SL between the two groups studied.

Figure 1. Selection of the study sample.



TPA. Transpalatal Arch. NB. Nance Button

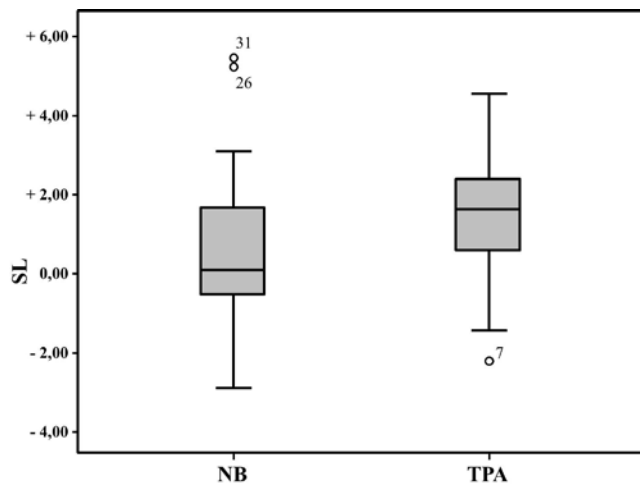
**Table 1. Loss of space in the study groups.**

Space maintainer	Mean (mm)	Confidence Interval		Standard Deviation	Kolmogorov-Smirnov. Sig.	Shapiro-Wilk. Sig.	T-Student. Sig.	Mann-Whitney. Sig.
		Lower Bound	Upper Bound					
TPA <sup>1</sup> (n=23)	1.336	0.550	2.122	1.817	0.200	0.460	0.211	0.154
NB <sup>2</sup> (n=31)	0.695	0.014	1.377	1.858	0.055	0.131		

<sup>1</sup> TPA. Transpalatal Arch.

<sup>2</sup> NB. Nance Button.

**Figure 2. Loss of space in the study groups.**



NB. Nance Button TPA. Transpalatal Arch. SL. Space Loss.

The SL was analysed in relation with the type of dental loss within each study group, obtaining that, although the SL was greater in the cases in which one or two primary second molar were involved than in other situations, the difference was not statistically significant (Table 2). It is relevant to consider that, both in unilateral first molar lost in the TPA group and in bilateral first molar lost in NB group there is a slight gain of space between the start and the end of the study.

Statistically significant differences were found in SL between the two study groups in the unilateral loss of second primary molars (p Mann-Whitney = 0.03), the data report that the SL in the TPA group (2.50mm) is considerably greater than in the NB group (0.22mm) (Table 3).

**Evaluation of the changes in the molar relationship**

The initial and final molar relationship could be assessed in 49 cases, obtaining that a 28.6% of the TPA group developed a mesialization of the upper arch, in contrast to the 17.9% of the NB group (Figure 3). Although changes in the molar relationship were most frequent in the TPA group, the differences were not statistically significant (p Fisher = 0.539)

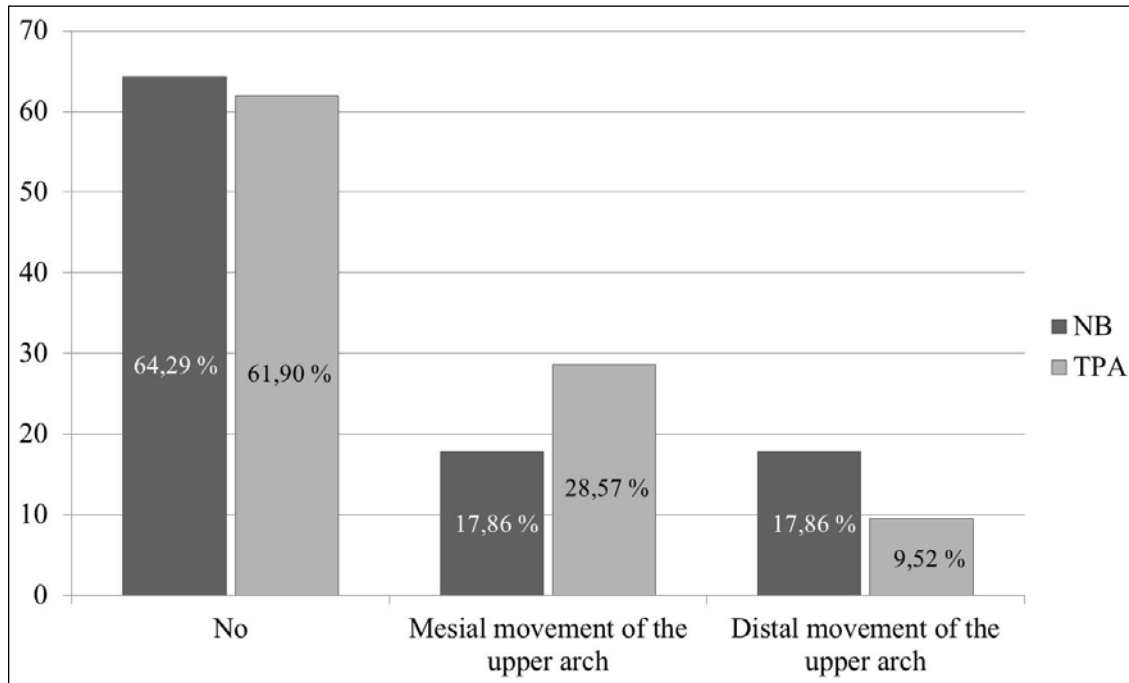
**Table 2. Loss of space depending of the type of dental loss.**

Space maintainer	Dental loss (primary molars)	Mean (mm)	Kruskal Wallis. Sig.
TPA <sup>1</sup> (n=23)	2 <sup>nd</sup> molar unilateral (n=7)	2.50	0.065
	2 <sup>nd</sup> molar bilateral (n=2)	3.21	
	1 <sup>st</sup> molar unilateral (n=3)	-0.31	
	1 <sup>st</sup> molar bilateral (n=7)	0.20	
	1 <sup>st</sup> and 2 <sup>nd</sup> molar contralateral (n=2)	1.93	
	1 <sup>st</sup> and 2 <sup>nd</sup> molar unilateral (n=2)	1.23	
	>2 molars (n=0)	—	
NB <sup>2</sup> (n=31)	2 <sup>nd</sup> molar unilateral (n=3)	0.22	0.082
	2 <sup>nd</sup> molar bilateral (n=4)	0.09	
	1 <sup>st</sup> molar unilateral (n=1)	2.58	
	1 <sup>st</sup> molar bilateral (n=7)	-0.66	
	1 <sup>st</sup> and 2 <sup>nd</sup> molar contralateral (n=0)	—	
	1 <sup>st</sup> and 2 <sup>nd</sup> molar unilateral (n=2)	0.29	
	>2 molars (n=14)	1.57	

<sup>1</sup> TPA. Transpalatal Arch.

<sup>2</sup> NB Nance Button.

Figure 3. Changes of the molar relationship depending of the type of the space maintainer.



NB. Nance Button TPA. Transpalatal Arch.

Table 3. Comparison of the loss of space in the two study groups depending of the type of dental loss.

Dental loss (primary molars)	Space Maintainer	Loss of space. Mean (mm)	Mann-Whitney. Sig.
2 <sup>nd</sup> molar unilateral	TPA <sup>1</sup> (n=7)	2.50	0.030*
	NB <sup>2</sup> (n=3)	0.22	
2 <sup>nd</sup> molar bilateral	TPA (n=2)	3.21	0.064
	NB (n=4)	0.09	
1 <sup>st</sup> molar unilateral	TPA (n=3)	-0.31	0.180
	NB (n=1)	2.58	
1 <sup>st</sup> molar bilateral	TPA (n=7)	0.20	0.480
	NB (n=7)	-0.66	
1 <sup>st</sup> and 2 <sup>nd</sup> molar contralateral	TPA (n=2)	1.93	—
	NB (n=0)	—	
1 <sup>st</sup> and 2 <sup>nd</sup> molar unilateral	TPA (n=2)	1.23	1
	NB (n=2)	0.29	
>2 molars	TPA (n=0)	—	—
	NB (n=14)	1.57	

<sup>1</sup> TPA Transpalatal Arch

<sup>2</sup> NB Nance Button

\*Statistically significant (p<0.05)

## DISCUSSION

In the present study, the loss of space in the TPA group (1.336mm) was almost double that obtained in NB group, although without statistically significant differences. Our results agree with those obtained in previous research<sup>14</sup> in which the space loss with TPA was greater than the obtained with NB, also without significant differences. Considering that the leeway space in the maxillary lateral sector in Spanish children is between 0.9-1mm<sup>15</sup>, the average

loss of space in the use of TPA as a space maintainer exceeds these data, and by therefore it is to be considered clinically relevant.

The scientific evidence for or against the placement of space maintainers after premature dental loss is poor<sup>10</sup>; even the AAPD recognizes the need for randomized clinical trials to determine the efficacy of space maintainers, analysing the costs and side effects of their utilization<sup>16</sup>. The loss of the leeway space increases the need and complexity of subsequent orthodontic treatment, and therefore, the use of space maintainers is necessary to preserve the total arch length decreasing the prevalence and severity of malocclusions associated with premature dental loss<sup>17</sup>. Some scientific authors do not consider the use of space maintenance appliances in cases with a large dentoalveolar bone discrepancy or when the loss of space was not anticipated and has already occurred, since the patient will surely require posterior corrective orthodontic treatment<sup>18</sup>. In addition, proper control of oral hygiene is imperative, because the appliances act as a risk factor for the development of gingival and/or periodontal disease<sup>19</sup>.

Our evaluation of the SL in the different types of dental loss reveals that it is superior in those cases with the involvement of one or both primary second molars, without statistically significant differences with the rest of the types of situations. Previous researches agree with our result that the posterior lateral SL is superior when second temporal molars are lost, compared to the first temporal molars, with negative consequences on the space required for the eruption of permanent successors<sup>20-23</sup>. Therefore, the use of space maintainers is recommended whenever primary second molar or molars are lost<sup>24</sup>.

The prescription of space maintainer when first primary molars are lost is controversial in the scientific literature. After the loss of the first temporary molar, there is a loss of approximately 1mm lost per side in the maxilla<sup>25,26</sup>, although the results of the Seward research with a five-year follow-up establish that the SL can range from 2-7.3mm<sup>27</sup>. Alexander et al found that the

SL is not significant in patients with a meso or brachyfacial pattern, but it is significant in those with a dolichofacial pattern<sup>28</sup>. Regarding the decreasing arch length mechanism, or leeway space loss, some authors affirm that it is due to the distalization of the primary canine<sup>25, 29</sup>, while others establish that a mesialization of the posterior teeth occurs<sup>21, 27</sup>, surely being produced by a mixture of both mechanisms<sup>9</sup>. A large number of researchers consider that the SL produced in these cases is clinically insignificant with no specific differences in the position of the permanent molar, so they do not recommend the use of space maintainers, especially if the lost is unilateral or if it has been established a stable occlusion (angle class I) between the permanent molars<sup>17, 25, 29-31</sup>. However, the use of space maintainers is recommended when crowding is severe, in order to facilitate subsequent corrective phase 2 orthodontics<sup>24</sup>.

TPA and NB are both bilateral fixed appliances frequently used in multiple dental loss as space maintainers. Hill et al carried out an analysis of the maintainers used in a children's dental care program, stating that although TPA is not used frequently, it provides minimal problems and does maintain space<sup>32</sup>. TPA is a good alternative to NB, since it allows the expansion, derotation and torque variation of the permanent molars, increasing vertical control<sup>33</sup>. Furthermore, the TPA is more compatible with soft tissues than the NB, as it is more hygienic, and more comfortable<sup>14, 33</sup>. However, although it is possible to control or correct the mesiopalatine rotation of the first permanent molars with TPA better than with NB<sup>14</sup>, the effect on mesial position, molar drifting or on space recovery is unpredictable<sup>13, 14</sup>. In theory, the TPA performs its function of maintaining space by preventing or counteracting the mesiopalatine rotation of the permanent molars by forces exerted by the central omega. Therefore, the TPA would only be indicated when at least one primary second molar is present, being totally contraindicated in bilateral second primary molars lost, since it would cause an in block mesialization of both first permanent molars. The NB, having the third support through acrylic in the palatal ridges, avoids mesial movement or rotation of the permanent molars. The scientific literature consulted recommends the use of NB in bilateral or multiple dental losses as a fixed space maintainer, while if a primary second molar remains, NB or TPA can be used indifferently<sup>17, 33</sup>.

In the present study, we found that in four cases the space maintainer had been placed for the loss of a first primary molar, and in 14 cases for bilateral loss of first primary molars. In all situations, with the exception of one treated with NB, the SL when using space maintainer was insignificant, even increasing the D-E space slightly. Other factors that would act three-dimensionally on the dental arch should be considered in relation to the increase of the leeway space, such as the increase in bicanine width with the eruption of the lateral

incisors, which could explain the apparent increase in the D-E space. The absence of significant differences between the two maintainers supports that both the TPA and the NB would be effective in the event of loss of the primary first molars, and, therefore, the TPA could be a more hygienic and comfortable device for the patient than the NB.

It is striking that, in the present study, all the cases in which primary second molars are involved, the SL with TPA always exceeds the leeway space, whereas when they were treated with NB, it only exceeds it in an isolated case of unilateral loss of a primary first molar. However, the results were only statistically significant in the unilateral losses of the deciduous second molars, since the SL using TPA significantly exceeded the situations treated with NB, being almost ten times higher. Surely, the results in the rest of the premature losses were not statistically significant due to the small sample size. Therefore, although the previous research recommends the use of TPA in situations with the persistence of a primary second molar, based on our results, we believe that the prescription of this appliance as a space maintainer should be restricted only to uni or bilateral losses of primary first molars.

According to the previous authors, in losses of more than two primary molars, the only appliance used in our sample was the NB, so a comparison with the TPA could not be established. It would be necessary to determine if the SL in this case (1.57mm) engaging bilaterally first and second primary molars, has occurred due to mesialization of the permanent molars or distalization of the temporary canines, however, this assessment can not be performed with radiographic records.

The initial and final molar relationship was evaluated to determine the possible effect of mesialization of the first permanent molars secondary to SL in relation to definitive occlusion. 49 cases could be evaluated and five had to be excluded because at the time of the placement of the appliance, the occlusion of the permanent molars had not yet been established. Furthermore, we must consider that the maxillary-mandible occlusal relationship is also influenced by the changes that occurred in the mandible which were not considered in our data collection. According to our data, mesialization of the first permanent molars, with a distocclusion effect on the mandible, was found in a higher percentage of cases treated with TPA than with NB, but with no significant differences.

## CONCLUSIONS

The loss of the leeway space using a TPA as a space maintainer (1.336mm) is greater than using a NB (0.695mm). The loss of the space when a TPA is used exceeds the leeway space in all cases in which the loss of one or both second primary molar is involved, therefore its use is only recommended in first primary molar losses.

## REFERENCES

1. Hutchinson SJ. On the premature extraction of deciduous canines. *Br Dent Assoc J* 5:75-82, 1884.
2. Davenport IB. The significance of the natural form and arrangement of the dental arches of a man, with a consideration of the changes which occur as a result of their artificial derangement by filing or by the extraction of teeth. Read before the New York Odontological Society, April 12<sup>th</sup>, Reprinted from the *Dental Cosmos* for July, 1887.
3. Monte-Santo AS, Viana SV, Moreira KMS, Imparato JCP, Mendes FM, Bonini GA. Prevalence of early loss of primary molar and its impact in schoolchildren's quality of life. *Int J Paediatr Dent* 28(6):595-601, 2018.
4. Bansal M, Gupta N, Gupta P, Arora V, Thakar S. Reasons for extraction in primary teeth among 5-12 years school children in Haryana, India-A cross-sectional study. *J Clin Exp Dent* 9(4): e545, 2017.
5. Qudeimat MA, Fayle SA. The use of space maintainers at a UK pediatric dentistry department. *ASDC J Dent Child* 66(6):383-6, 1999.
6. Ahamed SSS, Reddy VN, Krishnakumar R, Mohan MG, Sugumaran DK, Rao AP. Prevalence of early loss of primary teeth in 5-10-year-old school children in Chidambaram town. *Contemp Clin Dent* 3(1):27, 2012.
7. Richardson ME. The relationship between the relative amount of space present in the deciduous dental arch and the rate and degree of space closure subsequent to the extraction of a deciduous molar. *Dent Pract Dent Rec* 16(3):111-8, 1965.
8. Clinch LM. A longitudinal study of the results of premature extraction of deciduous teeth between 3-4 and 13-14 years of age. *D Practitioner* 9:109-28, 1959.
9. Rönnerman A, Thilander B. Facial and dental arch morphology in children with and without early loss of deciduous molars. *Am J Orthod* 73(1):47-58, 1978.
10. Laing E, Ashley P, Naini FB, Gill DS. Space maintenance. *Int J Paediatr Dent* 19(3):155-62, 2009.
11. Bobak V, Christiansen RL, Hollister SJ, Kohn DH. Stress-related molar responses to the transpalatal arch: a finite element analysis. *Am J Orthod Dentofac Orthop* 112(5):512-8, 1997.
12. Ingervall B, Hönlgl KD, Bantleon H. Moments and forces delivered by transpalatal arches for symmetrical first molar rotation. *Eur J Orthod* 18(2):131-9, 1996.
13. Dahlquist A, Gebauer U, Ingervall B. The effect of a transpalatal arch for the correction of first molar rotation. *Eur J Orthod* 18(3):257-67, 1996.
14. Stivaros N, Lowe C, Dandy N, Doherty B, Mandall NA. A randomized clinical trial to compare the Goshgarian and Nance palatal arch. *Eur J Orthod* 32(2):171-6, 2010.
15. Marin Ferrer JM, Moreno González JP, Barbería Leache E, Alió Sanz JJ, Costa Ferrer F, de Nova García J, et al. El espacio de deriva. Estudio de una población española. *Ortodoncia española: Boletín de la Sociedad Española de Ortodoncia* 34(3):187-93, 1993.
16. AAPD. Management of the Developing Dentition and Occlusion in Pediatric Dentistry. *The Reference Manual of Pediatric Dentistry* 362-78, 2019-2020.
17. Terlaje RD, Donly KJ. Treatment planning for space maintenance in the primary and mixed dentition. *ASDC J Dent Child* 68(2):109-14, 2001.
18. Qudeimat MA, Fayle SA. The longevity of space maintainers: a retrospective study. *Pediatr Dent* 20:267-72, 1998.
19. Arikan F, Eronat N, Candan Ü, Boyacio lu H. Periodontal conditions associated with space maintainers following two different dental health education techniques. *J Clin Pediatr Dent* 31(4):229-34, 2007.
20. Northway WM, Wainright RL, Demirjian A. Effects of premature loss of deciduous molars. *Angle Orthod* 54(4):295-329, 1984.
21. Northway WM. The not-so-harmless maxillary: Primary first molar extraction. *J Am Dent Assoc* 131(12):1711-20, 2000.
22. Macena MCB, Katz CRT, Heimer MV, e Silva, Juliana Freire de Oliveira, Costa LB. Space changes after premature loss of deciduous molars among Brazilian children. *Am J Orthod Dentofac Orthop* 140(6):771-8, 2011.
23. Andreeva RS, Arnautska HI, Belcheva AB, Georgieva MT, Dimitrov EV. Loss of space according to the time and the type of the premature extracted deciduous teeth. *J of IMAB* 22(2):1169-71, 2016.
24. Rock WP. Extraction of primary teeth—balance and compensation. *Int J Paediatr Dent* 12(2):151-3, 2002.
25. Lin Y, Lin W, Lin YJ. Immediate and six-month space changes after premature loss of a primary maxillary first molar. *J Am Dent Assoc* 138(3):362-8, 2007.
26. Tunison W, Flores-Mir C, ElBadrawy H, Nassar U, El-Bialy T. Dental arch space changes following premature loss of primary first molars: a systematic review. *Pediatr Dent* 30(4):297-302, 2008.
27. Seward FS. Natural closure of deciduous molar extraction spaces. *Angle Orthod* 35(1):85-94, 1965.
28. Alexander SA, Askari M, Lewis P. The premature loss of primary first molars: Space loss to molar occlusal relationships and facial patterns. *Angle Orthod* 85(2):218-23, 2015.
29. Lin Y, Lin W, Lin YJ. Twelve-month space changes after premature loss of a primary maxillary first molar. *Int J Paediatr Dent* 21(3):161-6, 2011.
30. Lin YJ, Lin Y. Long-term space changes after premature loss of a primary maxillary first molar. *J Dent Sci* 12(1):44-8, 2017.
31. Park K, Jung D, Kim J. Three-dimensional space changes after premature loss of a maxillary primary first molar. *Int J Paediatr Dent* 19(6):383-9, 2009.
32. Hill CJ, Sorenson HW, Mink JR. Space maintenance in a child dental care program. *J Am Dent Assoc* 90(4):811-5, 1975.
33. Kupietzky A, Tal E. The transpalatal arch: an alternative to the Nance appliance for space maintenance. *Pediatr Dent* 29(3):235-8, 2007.