

# Role of Marginal Ridge Shape and Contact Extent in Proximal Caries Between Primary Molars

Vanessa Y Cho\* / Nigel M King\*\* / Robert P Anthonappa\*\*\*

**Objectives:** To determine different combinations of marginal ridge shape (MRS) and contact extents in nature of the contact between primary molars and its correlation with the presence of carious lesions on radiographic examination of approximal surfaces. **Study design:** Retrospective study of 347 clinical records, including photographs and bitewing radiographs, were assessed for intact MRS and caries extent. The carious lesions were scored (0-5, Mejàre scoring system) radiographically and correlated to the intact MRS on clinical photographs, and strength of associations quantified using logistic regression analysis and chi-square tests. **Results:** Primary molars, 848 (contact extent), and 757 (MRS) were analyzed. Combination of straight-convex (35.4%) MRS was more common ( $p < 0.001$ ). None of the approximal surfaces were caries-free for straight and straight MRS with 36.4% of both approximal surfaces exhibiting caries in enamel, and 38.2% of one approximal surface exhibiting caries in dentin. Approximately 90% of the primary molars with substantial contacts exhibited carious lesions in the enamel and 80% with light contacts exhibited carious lesions in the dentin ( $p < 0.001$ ). **Conclusion:** Six different combinations of intact MRS were identified. Combination of concave-convex shapes exhibited caries extending into dentin. Substantial and/or light contacts between primary molars showed higher caries experience in the approximal surfaces.

**Keywords:** marginal ridge, primary molars, approximal caries, interproximal caries

## INTRODUCTION

The approximal surfaces are those surfaces which form points of contact between adjacent teeth. They are also known as interproximal surfaces. For consistency, the word approximal will be used throughout this text. Approximal carious lesions in primary molars are of frequent occurrence in children.<sup>1</sup> Clinical detection of caries in the approximal areas is challenging until there are visible signs of cavitation.<sup>2</sup>

Traditionally, textbooks describe primary molars to exhibit flat, broad and tight contacts,<sup>3</sup> which could be convex or concave in the buccolingual direction or the occlusal-cervical direction.<sup>4</sup> However, the primary molars are not always in contact, and so are the marginal ridges. Nevertheless, very few studies have examined the morphology of the contact areas and the nature of the contact, i.e. tight or open. Allison and Schwartz (2003) grouped the contacts between primary molars as open or closed, and they reported that 80% to 84% of their sample exhibited closed contacts.<sup>5</sup> Recently, Sun and co-workers stated that approximately 40% of the primary molars in their study showed tight contacts.<sup>6</sup> It is logical to assume that tight contacts or absence of interdental spacing can increase the caries risk in children, as they lead to food and plaque impaction resulting in microbial colonisation and subsequent development of carious lesions.<sup>7</sup> Furthermore, Almer-Nielsen and Madsen, concluded that plaque accumulation, bleeding on probing, and surface-formed contact (broad contact area) between the primary molar teeth were useful predictors for approximal caries in the primary dentition.<sup>8</sup>

From The University of Western Australia, Paediatric Dentistry Department

\*\* Vanessa Y Cho, Paediatric dentist, The University of Western Australia, Paediatric Dentistry UWA Dental School.

\*\* Nigel M King, Professor.

\*\*\* Robert P Anthonappa, Associate Professor.

Send all correspondence to:

Robert P Anthonappa

The University of Western Australia, Paediatric Dentistry

17 Monash Avenue Perth, WA 6009

Australia

Phone: +61893467868

Fax: +61893467666

E-mail: robert.anthonappa@uwa.edu.au

Recently, Cortes and co-workers evaluated the predictive power of the morphology of the primary molar contact surfaces on caries development in young children.<sup>9</sup> They classified the surface morphology of adjacent, primary molar teeth as being concave and convex. They reported that the morphology of approximal surfaces in primary molar teeth, especially when both surfaces were concave, significantly increased the risk of developing caries. Furthermore, another recent classification (OXIS) for contact types grouped them into four sub-types, namely “O, X, I, and S”.<sup>10</sup> Among the four sub-types, the I (75.5%) sub-type occurred commonly in children aged three to four years.<sup>10-11</sup> While the use of CBCT imaging showed contact point at an occluso-cervical level, the study found that contact area occurred at the occlusal third, which can be correlated to occlusal views in clinical photographs to determine the overall marginal ridge shape.<sup>12</sup>

Consequently, the marginal ridge shape and its contact extent have an essential role in the occurrence of carious lesions in the approximal surfaces of the primary molars. To date, the association between marginal ridge shape, its contact extent, and approximal caries experience between primary molars has not been investigated. Therefore, this study aimed to determine different combinations of marginal ridge shape, the contact extents in occlusal view (nature of the contact) between primary molars, and its correlation with the presence of carious lesions on radiographic examination of approximal surfaces.

## MATERIALS AND METHOD

Ethics approval for this retrospective study was obtained from the Human Research Ethics committee of The University of Western Australia (reference RA/4/20/4254).

Only dental records of children who met the following inclusion criteria were included in the final sample: aged seven years or less (with a full set of primary teeth), the presence of all primary molars with intact entire marginal ridge, a complete set of clinical records including clinical photographs (frontal, maxillary and mandibular arches) and bitewing radiographs, and born in Australia. Any teeth with restorations were excluded. For determining marginal ridge shapes, primary molars without any contact, i.e. open contacts were excluded and only included for the assessment of contact extent.

As per the standard protocols, pediatric dental registrars usually take clinical intraoral photographs (frontal, maxillary and mandibular views) with a digital camera (Canon EOS Rebel T2i 550D; Canon Inc., Tokyo, Japan) fitted with a 100-mm macro-lens and a ring flash. All photographs were taken at 1:3 magnification using  $f/22$ . The photographs were used to determine the intact marginal ridge shape and contact extent. For this study, the approximal surfaces of primary molars (tooth 55 mesial, tooth 54 distal, tooth 65 mesial, tooth 64 distal, tooth 75 mesial, tooth 74 distal, tooth 85 mesial, tooth 84 distal) were examined. A preliminary analysis of 30 records were completed by two examiners revealed that some marginal ridge shapes did not fit the concave or convex types. Therefore, the types were modified from Cortes<sup>6</sup> to include three different approximal surfaces (the shape of the marginal ridge) as concave, convex and straight—see Figure 1. As the types were examined in groups, open contacts between primary molars were excluded for the final analysis.

The extent of contact between the second primary molars and first primary molar was recorded as open, light or substantial. The length of the entire distal marginal ridge on the first primary molar was used as a reference. The contact extent was recorded as light when the contact was less than half the full length, substantial if the contact extended past half of the entire length of the intact distal marginal ridge of the first primary molar—see Figure 2.

Bitewing radiographs for all children were taken using a film holder (Rinn XCP, Dentsply, Australia). Dental X-ray units (Planmeca, Pro-X Helsinki, Finland) operating at 8 mA and 60 kV with a round collimation unit and a focus-to-skin distance of 0.35 m was used. The X-ray units were equipped with electronic timers. Exposure time was set to 0.125 s. The imaging plate systems used Scan-X Air Techniques (Air Techniques, Germany).

The approximal surfaces were classified according to a scoring system described by Mejäre.<sup>2</sup> The scores are as follows, 0= no visible radiolucency, 1= radiolucency in the outer half of enamel, 2= radiolucency in the inner half of enamel, 3= radiolucency in the dentin; broken enamel-dentin border without obvious spread in the dentin, 4= radiolucency with obvious spread in the outer half of dentin (less than halfway to the pulp), and 5= radiolucency in the inner half of dentin (more than halfway to the pulp). The scores were grouped as caries-free (Mejäre<sup>2</sup> of 0) and caries (Mejäre<sup>2</sup> score of 1 to 5).

Two trained/calibrated dental examiners assessed clinical photographs and radiographs. For caries scores using radiographs, both examiners gave a lower score when in doubt or borderline. Children were excluded from the study if the quality of the radiographs was reduced or if there was substantial overlap present on the approximal surfaces, making diagnosis difficult. Data was entered into a separate dataset which was subsequently merged for analysis to adjust diagnosing caries on the mesial and distal surfaces of the primary molars.

Records of 30 children were examined as a preliminary investigation to test the inter-examiner consistency and then re-examined at a later date (1 month) to assess the intra-examiner’s reliability. The agreement of the examiners was found to be very good. Analysis of the repeated examinations gave Cohen’s Kappa scores of 0.82 (inter-examiner) and 0.90 (intra-examiner) for contact types, 0.87 (inter-examiner) and 0.89 (intra-examiner) for radiograph scores, and 0.93 (inter-examiner) and 0.95 (intra-examiner) for contact extent. Any uncertainties were discussed and redone.

Statistical analysis was performed with software R 8.2 (Stata Corporation, College Station, TX, USA). Chi-square testing was used, and p-values are reported to test if the approximal surface and the extent of caries differed among the contact extents. Logistic regression analysis was used, and p-values reported to examine the relation between the different combination of approximal surface types and the extent of caries. Following logistic regression, Tukey post hoc tests were performed to ascertain which percentages were significantly different, and the corresponding p-values reported.

Figure 1. Primary molar contact types showing combinations of concave, convex and straight profiles.

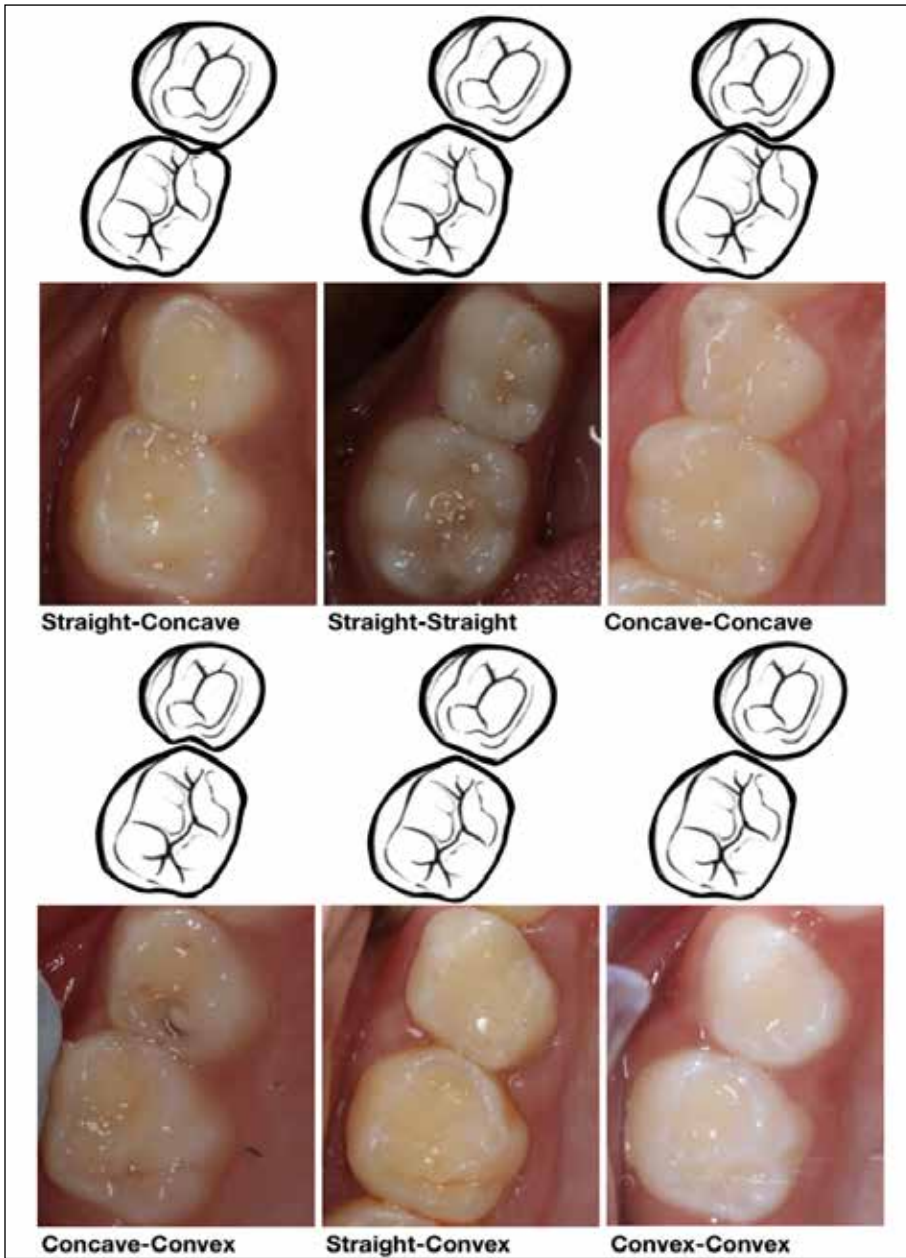
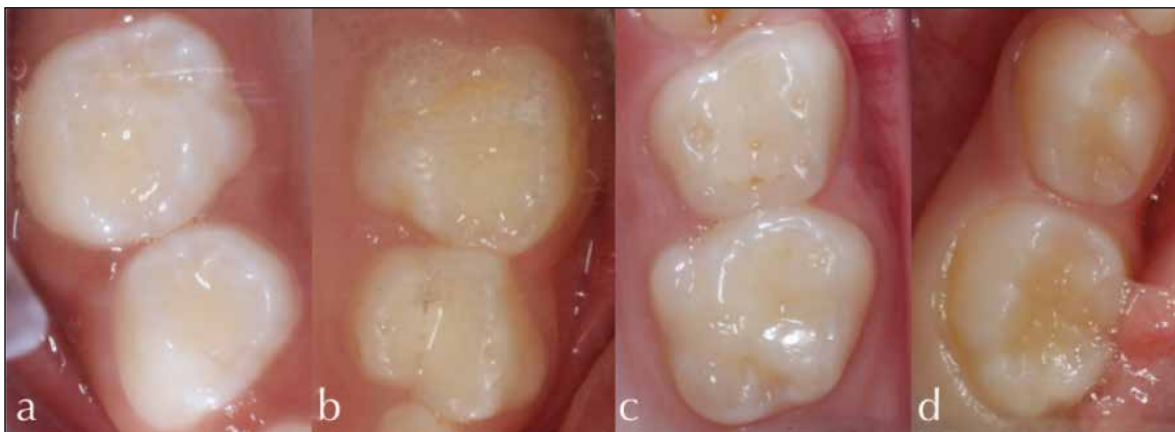

Figure 2. Primary molar contact extent classifications: a ) Light contact between teeth 54 and 55, b) Light contact between teeth 64 and 65, c) Substantial contact between teeth 64 and 65, and d) open or spacing between teeth 84 and 85.



**RESULTS**

A total of 347 dental records met the inclusion criteria, of which 848 primary molars were included for contact extent, and 757 primary molars for intact marginal ridge shape analysis. The records were selected without any attempt to have an even gender distribution, and there were 171 males and 176 females; thus, no statistical difference was evident. The most common combination of intact marginal ridge shapes was straight-convex (35.4%), followed by convex-convex (29.6%), concave-convex (22.2%), straight-straight (9%), concave-straight (2.5%), and concave-concave (1.3%) shapes, respectively ( $p < 0.001$ ), see -Table 1.

The various combinations of the intact marginal ridge shapes and the extent of the carious lesions on one or both approximal surfaces (both the distal surface of the first and mesial surface of the second primary molars) are listed in Table 1. For the combination of convex-convex marginal ridge shapes, only 23.8% of both the approximal surfaces were scored 0, i.e. no visible evidence of radiolucency or caries-free, 18.9% were scored 1 or 2 (i.e. radiolucency in the outer or inner half of enamel), and 5.9% were scored 3, 4 or 5 i.e. [radiolucency beyond the dentino-enamel junction (DEJ) and into the dentin]. Similarly, for the combination of concave-convex shapes, 16% were caries-free, 19.8% exhibited carious lesions in the outer or inner half of enamel, and 25.7% of both the approximal surfaces showed carious lesions beyond the DEJ and into the dentin. Interestingly, none of the approximal surfaces were caries-free for the combination of straight-straight shapes with 36.4% of both approximal surfaces exhibiting carious lesions in the outer or inner half of enamel, and 38.2% of one approximal surface exhibiting carious lesions beyond the DEJ and into the dentin. Logistic regression analysis, using the Tukey post hoc test did not reveal statistically significant difference for a particular combination of marginal ridge shape and approximal caries experience.

Light contacts (58.6%) were more commonly occurring, followed by substantial (30.7%), and open (10.7%) contacts. For the contact extent, 91.2% of the approximal surfaces were caries-free when there was an open contact. In comparison, only 15.7% and 6.7% of the approximal surfaces were caries-free for light and substantial contacts, respectively [ $p < 0.001$ ], see-Table 2]. When the primary molars exhibited a substantial contact, 81% of both the approximal surfaces exhibited carious lesions in the enamel, and 12.3% in the dentin. Similarly, When the primary molars exhibited a light contact, 48.5% of the approximal surfaces exhibited carious lesions in the enamel, and 35% in the dentin ( $p < 0.001$ ), see-Table 2.

**DISCUSSION**

Six different marginal ridge shapes were identified in the present study. The combination of a straight-convex shape occurred frequently followed by convex-convex, concave-convex, straight-straight, concave-straight, and concave-concave shapes, respectively. For the marginal ridge shape and caries extent in the enamel (Score 1 and 2) on one or both the approximal surfaces, straight-straight combination exhibited the highest number of carious lesions followed convex-convex, concave-concave, straight-convex, concave-convex, and concave-straight, respectively. Similarly, for the marginal ridge shape and caries extent in the dentin (score 3, 4 and 5) on one or both the approximal surfaces concave-straight exhibited the highest number of carious lesions followed by concave-convex, straight-straight, straight-convex, concave-concave, and convex-convex, respectively. However, no previous studies have investigated the marginal ridge shape and caries extent using Mejäre’s scoring system; hence a direct comparison was not possible. Nevertheless, the only published study to investigate marginal ridge shape and caries extent reported that a

**Table 1. Distribution of marginal ridge shapes between the primary molars and the corresponding radiograph score described by Mejäre<sup>2</sup>**

Marginal ridge shape	Prevalence (%) <sup>*</sup>	Caries free		Caries in enamel		Caries in dentin		95% Confidence Interval (%)
		One surface (%) <sup>*</sup>	Both surfaces (%) <sup>*</sup>	One surface (%) <sup>*</sup>	Both surfaces (%) <sup>*</sup>	One surface (%) <sup>*</sup>	Both surfaces (%) <sup>*</sup>	
Concave-Concave	1.3	23.9	18.2	19.5	11.1	18.2	9.1	(0.54, 34.30)
Concave-Straight	2.5	21.6	9.5	7.1	9.5	33.3	19	(6.34, 38.86)
Straight-Convex	35.4	24.7	5.2	13.8	14.3	33.2	8.8	(21.45, 30.19)
Straight-Straight	9.0	0	0	18.2	36.4	38.2	7.2	(1.86, 13.14)
Concave-Convex	22.2	8.8	16	4.8	19.8	24.9	25.7	(5.28, 13.55)
Convex-Convex	29.6	19.2	23.8	16.7	18.9	15.5	5.9	(4.02, 11.55)

Mejäre<sup>2</sup> scores:

Caries free: Mejäre<sup>2</sup> Score 0 = no visible evidence of radiolucency

Caries in enamel Mejäre<sup>2</sup> Score 1 and 2 = radiolucency in the outer and inner half of enamel respectively

Caries in dentin: Mejäre<sup>2</sup> Score of 3, 4, and 5 = radiolucency in the dentin; broken enamel-dentin border without obvious spread in the dentin, in the outer and inner half of dentin respectively

One surface (either distal of the first primary molar or mesial of the second primary molar)

Both surfaces (includes distal of the first primary molar and mesial of the second primary molar)

<sup>\*</sup> where p-value is <0.001 for Chi square analysis

**Table 2. The contact extent between primary molars and the corresponding radiograph score described by Mejäre<sup>2</sup> ( $p < 0.001$ )**

Contact extent	Prevalence (%) <sup>*</sup>	Caries free <sup>*</sup>			Caries in enamel <sup>*</sup>			Caries in dentin <sup>*</sup>		
		FPM (%)	SPM (%)	FPM+SPM (%)	FPM (%)	SPM (%)	FPM+SPM (%)	FPM (%)	SPM (%)	FPM+SPM (%)
Open	10.7	93.4	90.7	91.2	4.4	4.6	4.5	2.2	4.7	4.3
Light	58.6	24.3	4.6	15.7	35.9	65.8	48.5	39.8	29.6	35.8
Substantial	30.7	6.9	6.5	6.7	67.7	84.3	81.0	25.4	9.2	12.3

<sup>\*</sup> where p-value is <0.001 for Chi square analysis

where FPM: first primary molar, SPM: second primary molar

Mejäre<sup>2</sup> scores:

Caries free: Mejäre<sup>2</sup> Score 0 = no visible evidence of radiolucency

Caries in enamel Mejäre<sup>2</sup> Score 1 and 2 = radiolucency in the outer and inner half of enamel respectively

Caries in dentin: Mejäre<sup>2</sup> Score of 3, 4, and 5 = radiolucency in the dentin; broken enamel-dentin border without obvious spread in the dentin, in the outer and inner half of dentin respectively

concave-concave significantly influenced the risk of developing caries followed by concave-convex, convex-concave, and convex-convex types.<sup>9</sup> Again, given the different study methodology, it was impossible to compare the results.

The majority of the primary molar contacts identified were light and substantial types. Approximately, 81% of the primary molars with substantial contact exhibited caries in the enamel, while the primary molars with light contacts exhibited similar caries distribution in both the enamel (48.5%) and dentin (35.8%). Substantial contact between primary molars resulted in increased caries experience, which unfortunately could not be compared to other studies as this has not been investigated previously.

The shape of the intact marginal ridges was determined by evaluating the distal marginal ridge of the first primary molar and mesial marginal ridge of the second primary molar. Statistical analysis (Tukey post hoc test) of ridge shapes for the different combinations within the primary molars, i.e. concave on the first primary molar and convex on the second primary molar, compared to convex on the first primary molar and concave on the second primary molar, did not reveal any statistical difference, hence were combined into the concave-convex type.

The present study employed clinical photographs and radiographs to estimate the marginal ridge shape, contact extent and caries depth. This child-friendly assessment method is advantageous compared to using elastic bands for temporary elective separation to determine the morphology of the approximal surface of primary molar teeth, which by used by Cortes and co-workers.<sup>9</sup> However, the present study was retrospective in nature, which can be considered a limitation. The high inter- and intra-examiner scores, and the diagnosis based on photographs and radiographs with no access to clinical records by the two calibrated examiners strengthens these study findings. There is no doubt that dental caries is a multifactorial opportunistic infection; hence other variables such as ethnicity, oral hygiene, diet and habits may still contribute to the disease process. The nature of the sample

are records from a tertiary setting where a significant cohort are referred for management of carious lesions; thereby, it is considered a high-risk group for dental caries. Although this may not be a true reflection of the general population, children at high risk of caries may allow for more carious lesions in a smaller sample. Therefore, the large number of surfaces assessed, and the considerable number of carious lesions involved outweighs the potential sample bias. Furthermore, the strict inclusion criteria employed especially analysing teeth with intact marginal ridges, only strengthens the study design and findings. Nevertheless, future studies are essential to explore the predictive values of contact types and approximal caries experience in different populations and other risk-groups.

**CONCLUSIONS**

Six different combinations of marginal ridge shapes were identified. Of these, straight-convex marginal ridge shape occurred most commonly, and concave-convex shapes revealed the most significant number of carious lesions extending into dentine. Light and/or substantial contact between primary molars exhibited a higher caries experience in the approximal surfaces.

**Acknowledgements**

The authors wish to sincerely thank the Australian Dental Research Foundation (Ref:51001400) for its financial support of this research.

**Conflict of interest**

The authors report no conflicts of interest and are alone responsible for the content and writing of the paper.

**Author contributions:**

V.C, N.K and R.A designed the study, V.C collected the data, V.C and R.A analysed the data, V.C drafted the manuscript, N.K proofread the manuscript and R.A designed finalised the manuscript.

## REFERENCES

1. Dean J, Barton D, Vahedi I, Hatcher E. Progression of Interproximal Caries in the Primary Dentition. *J Clin Pediatr Dent*;22:59-62. 1997.
2. Mejäre I, Källestål C, Stenlund H. Incidence and Progression of Approximal Caries from 11 to 22 Years of Age in Sweden: A Prospective Radiographic Study. *Caries Res*;33:93-100. 1999.
3. McDonald RE, Avery DR. *Dentistry for the Child and Adolescent*. Mosby Incorporated. 2004.
4. Carlsen O. *Dental morphology*. Munksgaard, Copenhagen. 1987.
5. Allison PJ, Schwartz S. Interproximal Contact Points and Proximal Caries in Posterior Primary Teeth. *Pediatr Dent*;25:334-340. 2003.
6. Sun K.T., Li YF, Hsu JT, Tu MG, Hung CJ, Hsueh YH, Tsai HH. Prevalence of Primate and Interdental Spaces for Primary Dentition in 3- to 6-Year-Old Children in Taiwan. *J Formos Med Assoc*;117:598-604. 2018.
7. Warren J, Slayton R, Yonezu T, Kanellis M, Levy S. Interdental spacing and caries in the primary dentition. *Pediatr Dent*;25:109-13. 2003.
8. Almer Nielsen L, Madsen DB. Selektiv brug af bitewing-undersøgelse til diagnostik af approximal caries i primære molarer. *Tandlægebldet*;109:370-374. 2005.
9. Cortes A, Martignon S, Qvist V, Ekstrand K. Approximal Morphology as Predictor of Approximal Caries in Primary Molar Teeth. *Clin Oral Invest*;22:951-959. 2018.
10. Kirthiga M, Muthu M, Kayalvizhi G, Krithika C. Proposed Classification for Interproximal Contacts of Primary Molars Using Cbct: A Pilot Study. *Wellcome open research*;3. 2018
11. Muthu M, Kirthiga M, Kayalvizhi G, Mathur V. OXIS Classification of Interproximal Contacts of Primary Molars and Its Prevalence in Three- to Four-Year-Olds. *Pediatr Dent*;42:197-2. 2020.
12. Kirthiga M, Muthu M, Lee J, Kayalvizhi G., Mathur P, Song J, Rajesh P. Prevalence and correlation of OXIS contacts using Cone Beam Computed Tomography (CBCT) images and photographs. *Int J Paed Dent*;00:1-8. 2020.