

Postoperative Bleeding Complications after Stainless Steel Crown Placement: A Case Series

Colleen Helder */Jenelle Fleagle **/Lida Alimorad ***/Michael Cottam****

Stainless steel crown (SSC) placement is a common pediatric restorative treatment, generally completed with minimal complications. Discussed in this case series are two patients who presented to the emergency department (ED) with moderate oral bleeding persisting more than 12 hours after oral rehabilitation under general anesthesia. Bleeding incidence after pediatric oral rehabilitation has been found to range from 20% to 40%, with most being considered mild and significantly associated with extractions. There is limited documentation regarding moderate, persistent postoperative bleeding associated with placement of preformed metal crowns. The objective of this paper is to raise awareness of postoperative bleeding following SSC placement, discuss probable causes to minimize complications in the future, and discuss the local measures that were used to obtain hemostasis.

Keywords: *delayed postoperative bleeding, postoperative complications, stainless steel crowns, preformed metal crowns, pediatric dentistry.*

INTRODUCTION

For almost 70 years, stainless steel crowns (SSC) have been used in the treatment of dental decay because of their durability, inexpensiveness, efficiency, and efficacy.¹ It is estimated that 20% of children two to five years of age have dental caries,² with many likely receiving restorative therapies such as SSCs. Indications for SSC placement include extensive caries, cervical decalcification, and developmental defects. The durability and predictability of SSCs make them particularly useful in management of high-risk children undergoing oral rehabilitation under general anesthesia.³ The technique involved usually generates a minimal amount of self-limiting bleeding. Continuous oral bleeding is an unusual event in a patient without an underlying medical disorder.⁴ More unusual is persistent moderate postoperative bleeding following SSC placement.^{5,6} This case series is the first of our knowledge to formally discuss persistent postoperative bleeding associated with SSC placement.

Case 1

A three-year-old female with a history of asthma, obstructive sleep apnea, and four-month post-surgical history of uncomplicated tonsillectomy and adenoidectomy (T&A) presented to the Nemours/Alfred I. duPont Hospital for Children's (AIDHC) emergency department (ED) 12 hours after oral rehabilitation because of persistent gingival bleeding around a lower right SSC. The treatment was completed in an outpatient ambulatory surgical center (ASC), and the patient presented with bilateral first mandibular molar SSCs, two anterior crowns, and composite restorations. The history as reported by the patient's mother included oral bleeding

From the Division of Dentistry, Nemours/Alfred I. duPont Hospital for Children, Wilmington, DE, USA

*Colleen Helder, DMD

**Jenelle Fleagle, DDS,

***Lida Alimorad, DDS,

****Michael Cottam, DMD,MS

Corresponding author:

Colleen Helder,

Division of Dentistry

Nemours/Alfred I. duPont Hospital for Children

1600 Rockland Road

Wilmington, DE 19803

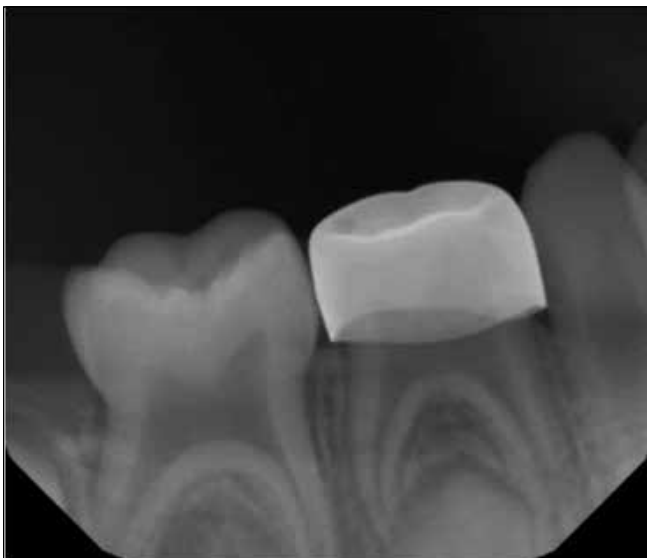
Phone: +302-298-7338

E-mail: colleen.helder@nemours.org

that was present upon discharge and continuation after application of gauze pressure at home. There were no known familial bleeding disorders; however, the father's medical history was unknown.

The patient presented with pallor, nausea, and some body bruising, but vital signs and capillary refill remained within normal limits. Upon examination, moderate bleeding was associated with the mandibular right first molar prepared with an SSC. The remaining oral cavity exhibited no bleeding. A liver clot was removed three separate times by the ED team prior to the dentist's ED arrival. The initial treatment was compression with gauze using digital pressure in five-minute increments, but bleeding continued, causing gauze saturation. It did, however, allow for visualization of subgingival cement in the distal buccal sulcus of the tooth. The cement was debrided, revealing a deep periodontal pocket. The area was then irrigated, and digital compression was repeated, with no resolution. A dental radiograph (Fig. 1) was taken, showing no abnormal findings. Absorbable sterile mesh was compressed into the distal buccal sulcus, followed by syringing of 15.5% ferric sulfate around the remaining circumference of the SSC. Hemostasis was achieved, and the patient was monitored for 90 minutes to confirm resolution before discharge. Coagulation abnormalities, malnutrition, and pulpal involvement were unlikely but unable to be fully ruled out. Post-discharge, the patient's mother consulted with hematology; no clotting abnormalities were identified.

Figure 1. Periapical radiograph associated with Case 1. The presence of SSC and normal trabecular pattern of bone is observed.



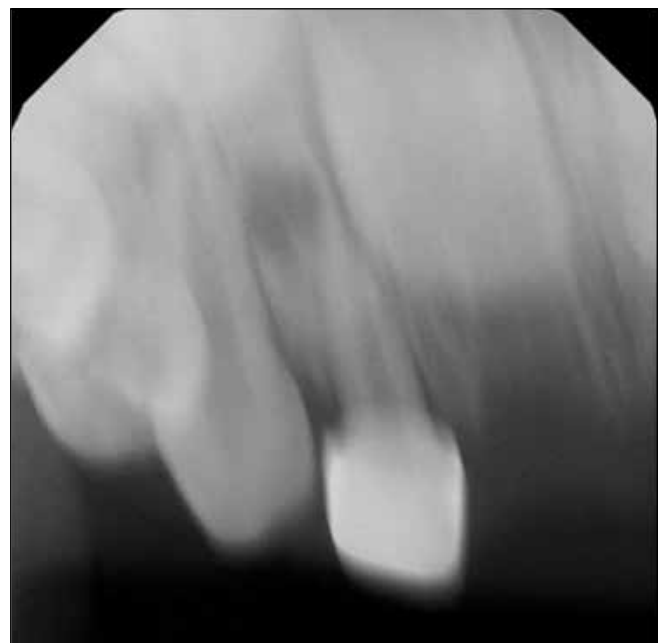
Case 2

A three-year-old female with a seven-month post-surgical history of uncomplicated T&A presented to the Nemours/AIDHC ED because of persistent gingival bleeding following a maxillary right lateral incisor crown procedure during oral rehabilitation under general anesthesia. The treatment had been completed at an ASC and included extractions, a white-veneered SSC, and restorations. Her dental history was significant for trauma three weeks previously, which the mother reported involved her maxillary anterior teeth, leading to the central incisors requiring extractions and the right lateral incisor a crown. Her family history was not significant for inherited bleeding disorders.

The patient presented hemodynamically stable and well appearing. Intraoral examination revealed bleeding to be localized to the maxillary anterior ridge. Gauze pressure was used to achieve temporary hemostasis to determine the precise area of bleeding. Upper right and left maxillary central incisor extraction sites contained what appeared to be absorbable gelatin sponge. The upper right maxillary lateral incisor, which had been restored with a white-veneered SSC, had persistent bleeding from the sulcus and from a 3-mm laceration on palatal tissue, adjacent to the crown. The tooth had class I mobility, and there were no signs of swelling or infection. Gauze pressure alone was not adequate to achieve hemostasis. A 15.5% ferric sulfate solution was then applied to the area using sterile gauze, along with digital pressure. This medicament only provided for 20-minute increments of hemostasis, after which very small amounts of breakthrough bleeding occurred from the gingival sulcus.

A radiograph was taken (Fig. 2) revealing a periapical radiolucency and a widened periodontal ligament, suggestive of necrosis secondary to the reported previous trauma. There was no sign of non-vital pulp therapy. The clinical impression was one of iatrogenic trauma involvement during tooth preparation, and, with the radiographic findings, this was likely exacerbated by a luxation injury. It was determined that extraction and placement of an absorbable gelatin sponge would be the best course of action. The upper right maxillary lateral incisor was extracted under moderate sedation and local anesthesia. Absorbable sponge was placed in the extraction socket, and hemostasis was achieved almost immediately. No direct pressure or suture was needed. The patient was monitored for an additional 50 minutes postoperatively with continued hemostasis. The dental follow-up the next day revealed a clotted extraction site with continued hemostasis. Mother reported that there was no further bleeding after ED discharge.

Figure 2. Periapical radiograph associated with Case 2. The presence of periapical radiolucency and widened periodontal ligament space associated with the right lateral incisor and recent extractions of the central incisors are observed.



DISCUSSION

In restorative dental procedures, some level of iatrogenic damage is inherently associated even with careful surgical technique.⁷ An SSC preparation is likely to result in soft tissue trauma to the immediately adjacent gingivae, even with utmost care. This is generally minimal, resulting in negligible amounts of self-limited bleeding. If, however, bleeding persists, systemic hematological bleeding disorders should be considered. In these cases, bleeding disorders were unlikely because of the lack of bleeding complications after T&A for both patients, the lack of known familial clotting disorders, and the fact that bleeding was limited to one area of the mouth, even though similar procedures occurred throughout the mouth.

In the first case, it appears iatrogenic trauma to the gingivae and alveolus likely occurred but was exacerbated by the presence of dental cement. Dental cement, like other foreign body matter, can cause delayed and continual reorganization of blood coagulum, resulting in liver clots.⁸ Liver clots are typically removed easily with suction, curette, or gauze,⁸ as was the case here. Because of bruising presentation, the oral bleeding, and lack of paternal history, outpatient coagulation studies were completed; however, no hematological abnormalities were found. The probable diagnosis is delayed post-surgical bleeding due to residual subgingival cement and iatrogenic soft tissue trauma during preparation.

In the second case, the etiology of bleeding was also likely multifactorial. It appeared to be caused by the palatal laceration of the periodontium; however, the tooth was also necrotic, likely secondary to previous luxation. It is plausible that treatment caused an acute exacerbation of a preexisting inflammatory process within the periodontal space of the tooth. Worth noting also was that no pulpal therapy was appreciated. This suggests that preoperative radiographs were likely not taken the day of surgery, or, if taken, the apical region was not captured or evaluated. An important consideration for traumatized teeth is that it can take up to three weeks for pulp necrosis and inflammatory root resorption to become radiographically evident.⁹ Preoperative films on the day of treatment should be considered when planning restorative therapy for recently injured teeth. In this case, non-vital pulp therapy or extraction would have been indicated.

Hemostasis was achieved locally in the first case by way of debridement, absorbable mesh, and ferric sulfate. Removal of debris decreases inflammation and promotes clot formation. The absorbable mesh, a sterile regenerated cellulose sheet, can be applied directly to the area of bleeding,¹⁰ in this case, the sulcus. Once in place, it swells into a brownish/black gelatinous mass promoting clot formation.¹⁰ The low pH of the mesh lends to wide-range bactericidal properties¹⁰ but may also cause delayed healing.⁴ It is normally absorbed within two weeks.⁴ Lastly, ferric sulfate reacts with blood causing agglutination of blood proteins, therefore occluding capillary orifices.¹¹

In the second case, hemostasis was achieved by tooth extraction and placement of a hydrocolloid absorbable gelatin sponge. This gelatin sponge is composed of porcine-derived collagen that is whipped into foam and then dried.¹⁰ Absorption of blood causes it to expand,¹⁰ lending to its hemostatic properties. Although it was not needed in our case, it is commonly used in conjunction with a figure-of-eight suture and application of pressure for several minutes.⁴ The gelatin sponge has a neutral pH, which allows it to be used as an adjunct with topical thrombin,¹⁰ and, lastly, it is absorbed in four to six weeks.^{4,10}

There are additional topical hemostasis agents that can be considered in these cases, including topical thrombin, epinephrine, and tranexamic acid. Although these cases were treated satisfactorily with local measures, differential diagnosis should include systemic considerations. These clinical scenarios are a reminder of the importance of careful diagnosis, procedure precision, and postoperative management to minimize postoperative bleeding complications.

Financial support and conflicts of interest:

No funding or competing interests.

REFERENCES

1. Seale NS. The use of stainless steel crowns. *Pediatr Dent* 24: 501-505, 2002.
2. Fleming E, Afful J. Prevalence of total and untreated dental caries among youth: United States, 2015–2016. CDC, NCHS. Available at: <https://www.cdc.gov/nchs/data/databriefs/db307.pdf>. Accessed April 20, 2020.
3. AAPD. Best Practices: Restorative Dentistry. The Reference Manual of Pediatric Dentistry. 2019. Available at: https://www.aapd.org/globalassets/media/policies_guidelines/bp_restorativedent.pdf. Accessed April 20, 2020.
4. Hupp JR, Ellis E, Tucker MR. *Contemporary Oral and Maxillofacial Surgery*. 5th ed. London; Elsevier; 2008:179-199.
5. Farsi N, Ba'akdah R, Boker A, Almushayt A. Postoperative complications of pediatric dental general anesthesia procedure provided in Jeddah hospitals, Saudi Arabia. *BMC Oral Health* 9: 6, 2009.
6. Mayeda C, Wilson S. Complications within the first 24 hours after dental rehabilitation under general anesthesia. *Pediatr Dent* 31: 513-519, 2009.
7. Mackenzie L. Technique tips—iatrogenesis and how to prevent it. *Dent Update* 44: 464-465, 2017.
8. Pandya D, Manohar B, Mathur LK, Shankarapillai R. "Liver clot"—a rare periodontal postsurgical complication. *Indian J Dent Res* 23: 419-422, 2012.
9. McTigue DJ. Overview of trauma management for primary and young permanent teeth. *Dent Clin North Am* 57: 39-57, 2013.
10. Peralta E. Overview of topical hemostatic agents and tissue adhesives. In: Cochran A, Collins KA, eds. *UptoDate*. Available at: <https://www.uptodate.com/contents/overview-of-topical-hemostatic-agents-and-tissue-adhesives#H1113557395>. Accessed April 20, 2020.
11. Bandi M, Mallineni SK, Nuvvula S. Clinical applications of ferric sulfate in dentistry: a narrative review. *J Conserv Dent* 20: 278-281, 2017.